

# The dancing doll

Yiu Shiobhon Luk<sup>1\*</sup>, Kai-hung Fung<sup>1</sup>

1. Department of Radiology, Pamela Youde Nethersole Eastern Hospital, Chai Wan, Hong Kong, China

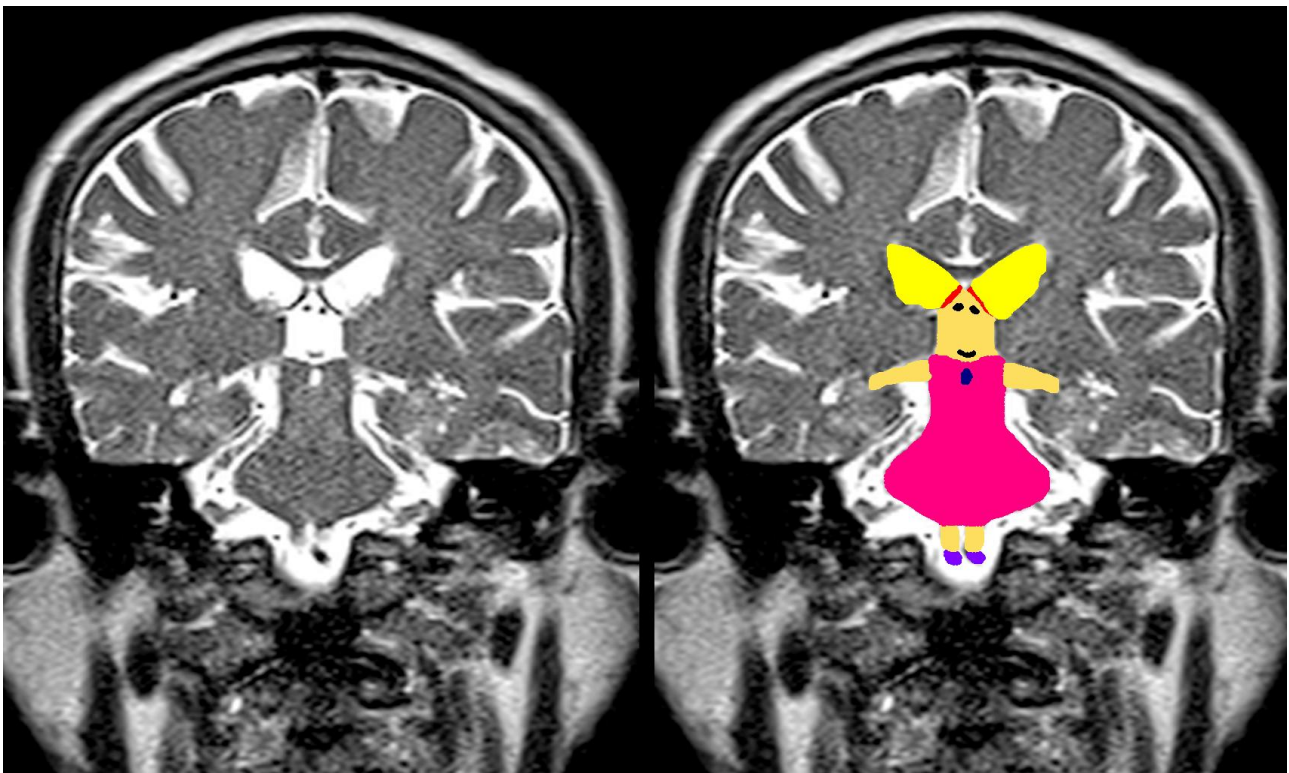
\* **Correspondence:** Yiu Shiobhon Luk, Department of Radiology, Pamela Youde Nethersole Eastern Hospital, 3 Lok Man Road, Chai Wan, Hong Kong, China  
(✉ [lys177@ha.org.hk](mailto:lys177@ha.org.hk))

Radiology Case. 2012 Apr; 6(4):31 :: DOI: 10.3941/jrcr.v6i4.1056

## INTERESTING IMAGE

### The dancing doll

A 66-year-old gentleman attended our department for an MRI scan of the brain as part of an investigation for recurrent episodes of tinnitus. As I was reading the T2 weighted coronal images, I was amused to see a lovely dancing doll (face formed by the third ventricle, eyes and lips formed by the cerebral vessels) showing off her ponytails (formed by the lateral ventricles) and beautiful dress (formed by the brainstem).



URL of this article:

[www.radiologycases.com/index.php/radiologycases/article/view/1056](http://www.radiologycases.com/index.php/radiologycases/article/view/1056)

Published by EduRad



[www.EduRad.org](http://www.EduRad.org)