

Noncontrast and contrast enhanced computed tomography for diagnosing acute appendicitis: A retrospective study for the usefulness

Maki Kitagawa^{1,2*}, Tatsuya Kotani¹, Yuji Miyamoto³, Yoshiaki Kuriu¹, Hideaki Tsurudome¹, Hiroshi Nishi¹, Masaharu Yabe¹, Eigo Otsuji²

1. Department of Surgery, Saiseikai Kyoto Hospital, Kyoto, Japan

2. Department of Digestive Surgery, Kyoto Prefectural University of Medicine, Kyoto, Japan

3. Department of Radiology, Shikaihoken Kobe Central Hospital, Kobe, Japan

* **Correspondence:** Maki Kitagawa, MD, Department of Surgery, Saiseikai Kyoto Hospital, Minamihirao, Imasato, Nagaokakyo, Kyoto 617-0814, Japan (✉ kitagawas@med.osaka-cu.ac.jp)

Radiology Case. 2009 Jun; 3(6):26-33 :: DOI: 10.3941/jrcr.v3i6.101

ABSTRACT

Abdominal computed tomography (CT) provides great benefits for the differential diagnosis in patients complaining of acute abdominal pain. However, the use of diagnostic X-rays is associated with the cumulative risk of cancer development. In order to determine the relative usefulness of noncontrast and enhanced CT with intravenous contrast material for diagnosing acute appendicitis, the retrospective analysis was performed using 247 patients (46 children and 201 adults) with clinically suspected appendicitis, who were admitted to our hospital from 2002 to 2006 and underwent noncontrast or combined noncontrast and enhanced CT examination. Of 185 patients who were diagnosed to have acute appendicitis with appendiceal thickening (167 cases) or normal-sized appendix (18 cases), 73 cases underwent noncontrast CT alone and these 73 cases could be retrospectively diagnosed to have appendicitis on noncontrast CT. On the other hand, 112 cases of these 185 patients underwent noncontrast CT followed by enhanced CT, and vermiform appendix was detected in 86 cases of them (86/112, 76.8%) on noncontrast CT. These 86 cases could be retrospectively diagnosed to have acute appendicitis on noncontrast CT, whereas enhanced CT was required to detect vermiform appendix and to obtain the final diagnosis of appendicitis in the remaining 26 cases (26/112, 23.2%). Enhanced CT was superior to noncontrast CT in diagnosing appendicitis in all age and any gender groups. We suggest that enhanced, but not noncontrast, CT should be primarily performed for diagnosing acute appendicitis in all patients to minimize the radiation exposure unless intravenous administration of contrast material is contraindicated.

ORIGINAL RESEARCH

INTRODUCTION

Acute appendicitis is one of the most common causes of acute abdominal pain, and is the most common condition that requires abdominal surgery in childhood (1-3). Acute appendicitis is caused by obstruction of the appendiceal lumen, leading to luminal distention, fluid accumulation, inflammation and, finally, perforation. The diagnosis of acute appendicitis can be frequently made on the basis of the history,

the physical examination, and the laboratory findings. However, approximately one third of patients with acute appendicitis present atypical clinical findings (4). In addition, many other abdominal disorders or conditions show the clinical findings indistinguishable from acute appendicitis, resulting in unnecessary removal of normal appendices (negative appendectomy) in many cases. Negative appendectomy may occur in 8-30% of the patients receiving appendectomy on the basis of suspected appendicitis (5-8).

Negative appendectomy can be avoided in the significant number by increasing the rate of accurate diagnosis with a help of modern diagnostic methods such as computed tomography (CT) (1-3).

Abdominal CT is a well-established technique and provides a highly sensitive and specific tool for the differential diagnosis in patients complaining of acute abdominal pain. The pathological conditions exhibiting acute abdominal pain may include acute appendicitis, colitis, diverticulitis, inflammatory bowel disease, bowel obstruction, adnexal cyst, acute cholecystitis, acute pancreatitis, and ureteral obstruction. It has been reported that the rate of accurate diagnosis for acute appendicitis is significantly increased with a help of abdominal CT, and the reported sensitivity and specificity for diagnosis of acute appendicitis are 91-100% and 91-99%, respectively (3, 6, 9-12). However, appropriate use of abdominal CT for diagnosing acute appendicitis is still controversial, since CT does have important disadvantages. These include the use of ionizing radiation, possible adverse reactions to the intravenous administration of contrast material, and potentially inadequate right lower quadrant visualization in thin individuals (4). It is generally accepted that, although diagnostic X-rays provide a great benefit, the use of diagnostic X-rays is associated with the cumulative risk of cancer development. In most developed countries, 0.6-1.8% of the cumulative risk of cancer to age 75 years may be ascribed to diagnostic X-rays. In Japan, which has the highest estimated annual exposure frequency of diagnostic X-rays in the world, the cumulative risk of cancer may increase to more than 3% (13, 14). In considering that the frequency of CT examination is rapidly increasing and the CT examination is partly responsible for the cumulative risk of cancer development (13), appropriate use of CT for diagnosing acute appendicitis should be determined to reduce the lifetime risk of cancer. Here, in order to determine the relative usefulness of noncontrast and enhanced CT with intravenous contrast material, we analyzed retrospectively 247 patients with clinically suspected appendicitis, who underwent noncontrast or combined noncontrast and enhanced CT examination for diagnosing acute appendicitis. The results suggest that enhanced, but not noncontrast, CT should be primarily performed for diagnosing acute appendicitis in all patients to minimize the radiation exposure unless intravenous administration of contrast material is contraindicated.

MATERIALS AND METHODS

The retrospective analysis was performed using 247 patients with clinically suspected appendicitis, who were admitted to our hospital from January 2002 to October 2006 and underwent noncontrast or combined noncontrast and enhanced CT examination. The patients were classified into four groups; child male (32 cases), child female (14 cases), adult male (111 cases), and adult female (90 cases). Children were defined as 0 to 15 years old. The diagnosis of acute appendicitis was made on the basis of the clinical symptoms, the physical findings, the laboratory data, and/or the X-ray and CT images. The accuracy of the diagnosis was assessed using the operation reports and the pathological reports of removed appendices.

The study was approved by the Ethical Committee at Saiseikai Kyoto Hospital.

Abdominal CT examination was performed by using the 4-MDCT scanner (multi-slice CT Aquillion 4, Toshiba Co., Tokyo, Japan) with the image thickness of 5-7 mm and the table speed of 4 mm/rotation. The enhanced CT images were obtained during the portal venous phase after intravenous administration of nonionic contrast material (Iopamiron, Bayer Schering Co., Tokyo, Japan; 90 ml for an adult; 2 ml/kg of body weight for a child with the maximum volume of 90 ml) at a rate of 1.5 ml/sec. Enhanced CT with oral or rectal contrast was not performed, since this method was not commonly used in Japan. The CT findings indicating the presence of acute appendicitis included appendiceal thickening (greater than 6 mm in the outer-wall-to-outer-wall transverse diameter), appendiceal wall thickening (greater than 3 mm), and/or appendiceal wall hyper-enhancement (4, 15, 16). Fecalith, periappendiceal fat stranding, thickening of the lateral conal fascia, abscess, ileocecal lymph node enlargement, focal thickening of terminal ileum or cecum, and/or the presence of extra- or intra-luminal air also suggested the presence of acute appendicitis, and these findings were especially helpful in the case of undetectable appendix (4, 17). Asymmetric thickening of the cecal wall, pericolonic inflammation, the presence of diverticula, and/or inflamed diverticula indicated the presence of diverticulitis (4, 18). The presence of appendicitis was excluded when normal appendix with no inflammatory signs was detected. The findings indicating normal appendix included visualization of the appendix to its blind ending tip, the diameter of less than 6 mm, and the absence of any inflammatory signs. The CT scans and the original radiology reports were re-reviewed by M.K. (surgeon), T.K. (surgeon), and Y.M. (experienced abdominal radiologist, the experience of 31 years).

Pearson's chi-square test was used to determine statistical significance.

RESULTS

The patient characteristics and the findings of CT images are summarized in Table 1, and the representative CT images are shown in Fig. 1. Of 247 patients examined, 143 cases were male and 104 cases were female; 46 cases were children (0 to 15 years old) and 201 cases were adults (more than 15 years old). Vermiform appendix was not detected in 40 of 247 patients (40/247, 16.2%); child male 8/32 (25.0%), child female 5/14 (35.7%), adult male 7/111 (6.3%), and adult female 20/90 (22.2%), respectively. When all (noncontrast and enhanced) CT images were analyzed, the detection rate of vermiform appendix was significantly ($p < 0.05$) higher in adult male patients (104/111, 93.7%) than that in the other patient groups; child male 24/32 (75.0%), child female 9/14 (64.3%), and adult female 70/90 (77.8%), respectively.

In this study, vermiform appendix was detected in 207 cases of 247 patients; appendiceal thickening in 174 cases, and normal-sized appendix in 33 cases, respectively. Based on the CT images, the laboratory data, and the clinical findings, 210 cases (210/247, 85.0%) were finally diagnosed to have acute appendicitis; appendiceal thickening in 167 cases, normal-

sized appendix in 18 cases, and undetectable appendix in 25 cases, respectively. The remaining 37 cases were diagnosed to have ascending colon diverticulitis (15 cases), colitis (8 cases), perforation of parts of the gastrointestinal tract other than appendix (2 cases), cecal cancer (1 case), appendiceal tumor (1 case), and unknown etiology (10 cases), respectively. Fecaliths were detected in 79 patients (79/247, 32.0%), and 76 cases of them (76/79, 96.2%) were accompanied with acute appendicitis, indicating the close relationship between fecalith and acute appendicitis (4). The frequency of fecalith was identical in all patient groups (Table 1). There was no case that exhibited significant adverse reactions to intravenous administration of contrast material.

Of 210 patients who were diagnosed to have acute appendicitis, appendectomy was performed in 182 cases (182/210, 86.7%); appendiceal thickening in 151 cases, normal-sized appendix in 11 cases, and undetectable appendix in 20 cases, respectively (Table 1). Of 182 patients who received appendectomy, 4 cases had been initially treated with intravenous administration of antibiotics according to the patient's decision, and exhibited the recurrence of appendicitis within 3 months thereafter. Repeated examination with noncontrast and enhanced CT was performed in these 4 patients, implying that these patients were finally exposed to high doses of radiation. Fecaliths had been detected in one case of these 4 patients on the initial CT examination. In considering the close relationship between fecalith and appendicitis, this patient should have received appendectomy at the initial attack to minimize the radiation exposure. The remaining 28 patients (28/210, 13.3%) were successfully treated with intravenous administration of antibiotics, and the decision of this treatment was made by the patients themselves on the informed consent.

As shown in Table 1, 210 cases of 247 patients were finally diagnosed to have acute appendicitis on the basis of the clinical, laboratory, and CT findings. Of these 210 cases with the final clinical diagnosis of acute appendicitis, vermiform appendix was detected in 185 cases on noncontrast or enhanced CT; appendiceal thickening in 167 cases, and normal-sized appendix in 18 cases, respectively (Table 2). Of these 185 cases with the diagnosis of appendicitis, 73 cases underwent noncontrast CT alone and these 73 cases could be retrospectively diagnosed to have acute appendicitis on noncontrast CT (column B in Table 2). On the other hand, 112 cases of these 185 patients underwent noncontrast CT followed by enhanced CT with intravenous contrast material (column C in Table 2). Vermiform appendix was detected in 86 cases (86/112, 76.8%) of these 112 patients on noncontrast CT; 7/11 (63.6%) in child male, 4/7 (57.1%) in child female, 49/58 (84.5%) in adult male, and 26/36 (72.2%) in adult female, respectively. These 86 cases could be retrospectively diagnosed to have acute appendicitis on noncontrast CT, whereas enhanced CT was required to detect vermiform appendix and to obtain the final diagnosis of appendicitis in the remaining 26 cases (26/112, 23.2%) (columns D and E in Table 2). The statistical analysis showed that enhanced CT was superior to noncontrast CT in diagnosing appendicitis, and enhanced CT was required to obtain the final diagnosis in at least 5-10 cases among 100 patients with acute appendicitis. The superiority of enhanced CT was particularly apparent in children and adult female patients (column F in Table 2). The

analysis of these 86 cases with the diagnosis of appendicitis shows that the detection rate of vermiform appendix on noncontrast CT appears to be higher in adult male patients than that in the other patient groups (column D in Table 2). However, no significant difference was detected statistically among these groups, presumably because of small numbers in some groups.

The pathological reports of removed appendices (182 cases) revealed catarrhal appendicitis in 22 cases, phlegmonous appendicitis in 106 cases, gangrenous appendicitis in 45 cases, chronic appendicitis in 1 case, and normal appendix in 8 cases, respectively (Table 3). The appendix was not detected on CT in one case with gangrenous appendicitis (noncontrast CT performed), and normal-sized appendix was detected in one case with gangrenous appendicitis (enhanced CT performed). As a result, negative appendectomy, which was defined as unnecessary removal of normal appendices on the clinical diagnosis of appendicitis, was performed in 8 patients (8/182, 4.4%); 4 cases in adult male (noncontrast CT performed in 4 cases), and 4 cases in adult female (noncontrast CT performed in 1 case, and enhanced CT performed in 3 cases); appendiceal thickening in 3 cases (1 case in male, and 2 cases in female [enhanced CT performed]), normal-sized appendix in 2 cases (2 cases in male), and undetectable appendix in 3 cases (1 case in male, and 2 cases in female [noncontrast CT performed in 1 case, and enhanced CT performed in 1 case]), respectively (Table 3).

DISCUSSION

The present study shows that enhanced CT is superior to noncontrast CT in diagnosing appendicitis in all age and any gender groups, and suggests that enhanced CT should be primarily performed for diagnosing acute appendicitis in all patients to minimize the radiation exposure unless intravenous administration of contrast material is contraindicated.

In this study, the patients were classified into four groups (child male, child female, adult male, and adult female), since CT images could be affected by the patient's body habitus, especially visceral fat content (1-3). The detection rate of vermiform appendix was significantly higher in adult male patients than in the other patient groups. The high detection rate of vermiform appendix in adult male patients may be ascribed to high content of visceral fat in these patients (19). Better visualization of vermiform appendix in adult male patients appears to lead to higher diagnostic rate of acute appendicitis on noncontrast CT alone as compared with the other patient groups (Table 2). However, no significant difference was detected statistically among these groups, presumably because of small numbers in some groups. Approximately 77% of all patients (112 cases) with the final diagnosis of appendicitis, that underwent combined noncontrast and enhanced CT examination, could be diagnosed on noncontrast CT alone (column D in Table 2). However, enhanced CT was required to detect vermiform appendix and to obtain the final diagnosis of appendicitis in the remaining 23% of these patients (column E in Table 2). These findings were true in any age and any gender groups, and enhanced CT was superior to noncontrast CT in

diagnosing acute appendicitis in any groups. In addition, there was no case that exhibited significant adverse reactions to intravenous administration of contrast material in our retrospective study. These findings suggest that enhanced, but not noncontrast, CT should be primarily performed for diagnosing acute appendicitis in all patients to minimize the radiation exposure unless intravenous administration of contrast material is contraindicated. It should be emphasized that the routine examination of noncontrast and enhanced CT as a set, which is often done in many institutions, should be avoided, although the examination of both CT as a set is really useful for obtaining sufficient information. It has been shown that enhanced CT with intravenous contrast material is especially useful for examining patients with minimal intra-abdominal fat, and provides a great benefit for detection of inflammatory appendiceal wall and complications such as abscess formation (Fig. 1), and for diagnosing other causes of abdominal pain such as pancreatitis and pyelonephritis (8).

Accurate clinical diagnosis is also very important to avoid unnecessary CT examination and to reduce the radiation exposure. In our study, 210 of 247 patients (210/247, 85.0%) with clinically suspected appendicitis were finally diagnosed to have appendicitis. Among them (210 cases), 182 cases received appendectomy, and 174 of them (174/182, 95.6%) were found to have actual appendicitis on the pathological reports. The remaining 28 patients were successfully treated with intravenous administration of antibiotics, suggesting that these patients also had acute appendicitis. The rate of accurate diagnosis in our study appears to be higher as compared with that of the previous reports, in which accurate diagnosis was finally made in less than a half of patients with clinically suspected appendicitis undergoing CT examination (6, 15, 19-22).

Various factors underlie missed diagnosis of acute appendicitis (3). These factors may include a misleading clinical history, paucity of intra-abdominal fat, presence of a small-bowel ileus, and lack of the typical CT signs of appendicitis. In our study, negative appendectomy was performed in 8 patients (8/182, 4.4%). Among them, normal-sized appendix was detected in 2 cases, and vermiform appendix was undetected in 3 cases, indicating lack of the typical CT signs of appendicitis. On the other hand, 3 cases show appendiceal thickening, a useful finding for diagnosing appendicitis, suggesting that careful evaluation with clinical signs and CT findings is required to improve further the accuracy of diagnosis of appendicitis (2). Recent studies with contrast-enhanced helical CT show that enlarged appendix, appendiceal wall thickening, periappendiceal fat stranding, and appendiceal wall enhancement are the most useful findings for diagnosing acute appendicitis (1, 17). It has been well documented that appendiceal CT with colon contrast is highly accurate (93-98%) for the diagnosis of appendicitis in adults (23). On the other hand, it has been reported that preoperative focused appendiceal CT with colon contrast does not increase the accuracy in diagnosing appendicitis in children (2). In the present study, we analyzed the usefulness of enhanced CT with intravenous contrast material, and showed that this method was really useful for detection of vermiform appendix in children and apparently increased the accuracy in diagnosing appendicitis in children (Fig. 1C, Table 2). However, the number of children studied here was small, and the analysis

with much more cases may be required to obtain the definite conclusion.

This is a retrospective, nonrandomized study and, therefore, has its limitations. We analyzed only the patients who were admitted to our hospital and underwent noncontrast or combined noncontrast and enhanced CT examination, and this study does not include an analysis of the patients who had CT examination that was interpreted as negative for appendicitis. In addition, not all patients with the final diagnosis of appendicitis received appendectomy, and we used the 4-MDCT scanner with the image thickness of 5-7 mm. These limitations prevent the determinations of the specificity, the sensitivity, and the negative predictive value.

The low detection rate of vermiform appendix in children may be ascribed to a paucity of visceral fat, and enhanced CT with intravenous contrast material could apparently increase the rate of accurate diagnosis of acute appendicitis in these patients (Table 2) (22). It has been shown that pediatric CT examination plays an important role in increased lifetime risk of cancer development. In fact, the lifetime cancer mortality risk attributable to radiation from pediatric CT examination is estimated to be considerably higher than that for adults (24). In addition, pediatric and young adult patients are up to 10 times more sensitive to the effects of radiation than are middle-aged and elderly adults (25). These findings indicate that repeated CT examination should be avoided in children, and suggest that enhanced CT should be primarily performed for children to minimize the radiation exposure. Recent advances in CT technology, including automated tube-current modulation, could reduce CT radiation exposure. Digital radiography with post-processing could also reduce the repeated radiation exposure (4).

The alternative tools include ultrasonography and magnetic resonance imaging (MRI), both of which have the great advantage of being radiation free. Although it has been shown that ultrasonography can increase the accuracy of diagnosis, there are still reservations regarding the sensitivity and/or specificity of ultrasonography (1, 2, 26, 27). It has been recently reported that abdominal MRI is a safe and reliable technique in patients suspected of having appendicitis, especially when used in a selected group of patients in whom ultrasonography is equivocal and CT is contraindicated (28). We suggest that abdominal CT examination for diagnosing acute appendicitis should be appropriately performed on the balance of benefits and risks, with an effort for minimizing the radiation exposure. Our retrospective study presented here suggest that enhanced, but not noncontrast, CT should be primarily performed for diagnosing acute appendicitis in all patients to minimize the radiation exposure unless intravenous administration of contrast material is contraindicated.

TEACHING POINT

Contrast enhanced CT is superior to noncontrast CT in diagnosing acute appendicitis. We suggest that enhanced, but not noncontrast, CT should be primarily performed for diagnosing acute appendicitis in all patients to minimize the radiation exposure unless intravenous administration of contrast material is contraindicated.

REFERENCES

1. See TC, Ng CS, Watson CJ, Dixon AK. Appendicitis: spectrum of appearances on helical CT. *Br J Radiol* 2002;75:775-781.
2. Stephen AE, Segev DL, Ryan DP, Mullins ME, Kim SH, Schnitzer JJ, Doody DP. The diagnosis of acute appendicitis in a pediatric population: to CT or not to CT. *J Pediatr Surg* 2003;38:367-371.
3. Levine CD, Aizenstein O, Lehavi O, Blachar A. Why we miss the diagnosis of appendicitis on abdominal CT: evaluation of imaging features of appendicitis incorrectly diagnosed on CT. *Am J Roentgenol* 2005;184:855-859.
4. Pinto Leite N, Pereira JM, Cunha R, Pinto P, Sirlin C. CT evaluation of appendicitis and its complications: imaging techniques and key diagnostic findings. *Am J Roentgenol* 2005;185:406-417.
5. Yu J, Fulcher AS, Turner MA, Halvorsen RA. Helical CT evaluation of acute right lower quadrant pain: part II, uncommon mimics of appendicitis. *Am J Roentgenol* 2005;184:1143-1149.
6. Lane MJ, Liu DM, Huynh MD, Jeffrey RB Jr, Mindelzun RE, Katz DS. Suspected acute appendicitis: nonenhanced helical CT in 300 consecutive patients. *Radiology* 1999;213:341-346.
7. Pena BM, Taylor GA, Fishman SJ, Mandl KD. Effect of an imaging protocol on clinical outcomes among pediatric patients with appendicitis. *Pediatrics* 2002;110:1088-1093.
8. Paulson EK, Kalady MF, Pappas TN. Clinical practice. Suspected appendicitis. *N Engl J Med* 2003;348:236-242.
9. Platon A, Jlassi H, Rutschmann OT, Becker CD, Verdun FR, Gervaz P, Poletti PA. Evaluation of a low-dose CT protocol with oral contrast for assessment of acute appendicitis. *Eur Radiol* 2009; in press.
10. Andre JB, Sebastian VA, Ruchman RM, Saad SA. CT and appendicitis: evaluation of correlation between CT diagnosis and pathological diagnosis. *Postgrad Med J* 2008;84:321-324.
11. Ceydeli A, Lavotshkin S, Yu J, Wise L. When should we order a CT scan and when should we rely on the results to diagnose an acute appendicitis? *Curr Surg* 2006;63:464-468.
12. Raman SS, Osuagwu FC, Kadell B, Cryer H, Sayre J, Lu DS. Effect of CT on false positive diagnosis of appendicitis and perforation. *N Engl J Med* 2008;358:972-973.
13. Berrington de Gonzalez A, Darby S. Risk of cancer from diagnostic X-rays: estimates for the UK and 14 other countries. *Lancet* 2004;363:345-351.
14. Herzog P, Rieger CT. Risk of cancer from diagnostic X-rays. *Lancet* 2004;363:340-341.
15. Rhea JT, Halpern EF, Ptak T, Lawrason JN, Sacknoff R, Novelline RA. The status of appendiceal CT in an urban medical center 5 years after its introduction: experience with 753 patients. *Am J Roentgenol* 2005;184:1802-1808.
16. Daly CP, Cohan RH, Francis IR, Caoili EM, Ellis JH, Nan B. Incidence of acute appendicitis in patients with equivocal CT findings. *Am J Roentgenol* 2005;184:1813-1820.
17. Choi D, Park H, Lee YR, Kook SH, Kim SK, Kwag HJ, Chung EC. The most useful findings for diagnosing acute appendicitis on contrast-enhanced helical CT. *Acta Radiol* 2003;44:574-582.
18. Yu J, Fulcher AS, Turner MA, Halvorsen RA. Helical CT evaluation of acute right lower quadrant pain: part I, common mimics of appendicitis. *Am J Roentgenol* 2005;184:1136-1142.
19. Ege G, Akman H, Sahin A, Bugra D, Kuzucu K. Diagnostic value of unenhanced helical CT in adult patients with suspected acute appendicitis. *Br J Radiol* 2002;75:721-725.
20. Lane MJ, Katz DS, Ross BA, Clautice-Engle TL, Mindelzun RE, Jeffrey RB Jr. Unenhanced helical CT for suspected acute appendicitis. *Am J Roentgenol* 1997;168:405-409.
21. Kaiser S, Jorulf H, Soderman E, Frenckner B. Impact of radiologic imaging on the surgical decision-making process in suspected appendicitis in children. *Acad Radiol* 2004;11:971-979.
22. Kaiser S, Finnbogason T, Jorulf HK, Soderman E, Frenckner B. Suspected appendicitis in children: diagnosis with contrast-enhanced versus nonenhanced Helical CT. *Radiology* 2004;231:427-433.
23. Rao PM, Rhea JT, Novelline RA, Mostafavi AA, McCabe CJ. Effect of computed tomography of the appendix on treatment of patients and use of hospital resources. *N Engl J Med* 1998;338:141-146.
24. Brenner DJ, Elliston CD, Hall EJ, Berdon WE. Estimated risks of radiation-induced fatal cancer from pediatric CT. *Am J Roentgenol* 2001;176:289-296.
25. Slovis TL. CT and computed radiography: the pictures are great, but is the radiation dose greater than required? *Am J Roentgenol* 2002;179:39-41.
26. van Randen A, Bipat S, Zwinderman AH, Ubbink DT, Stoker J, Boermeester MA. Acute appendicitis: meta-analysis of diagnostic performance of CT and graded compression US related to prevalence of disease. *Radiology* 2008;249:97-106.
27. Kosaka N, Sagoh T, Uematsu H, Kimura H, Yamamori S, Miyayama S, Itoh H. Difficulties in the diagnosis of appendicitis: review of CT and US images. *Emerg Radiol* 2007;14:289-295.
28. Cobben L, Groot I, Kingma L, Coerkamp E, Puylaert J, Blickman J. A simple MRI protocol in patients with clinically suspected appendicitis: results in 138 patients and effect on outcome of appendectomy. *Eur Radiol* 2009; in press.

FIGURES & TABLES

Noncontrast

Enhanced

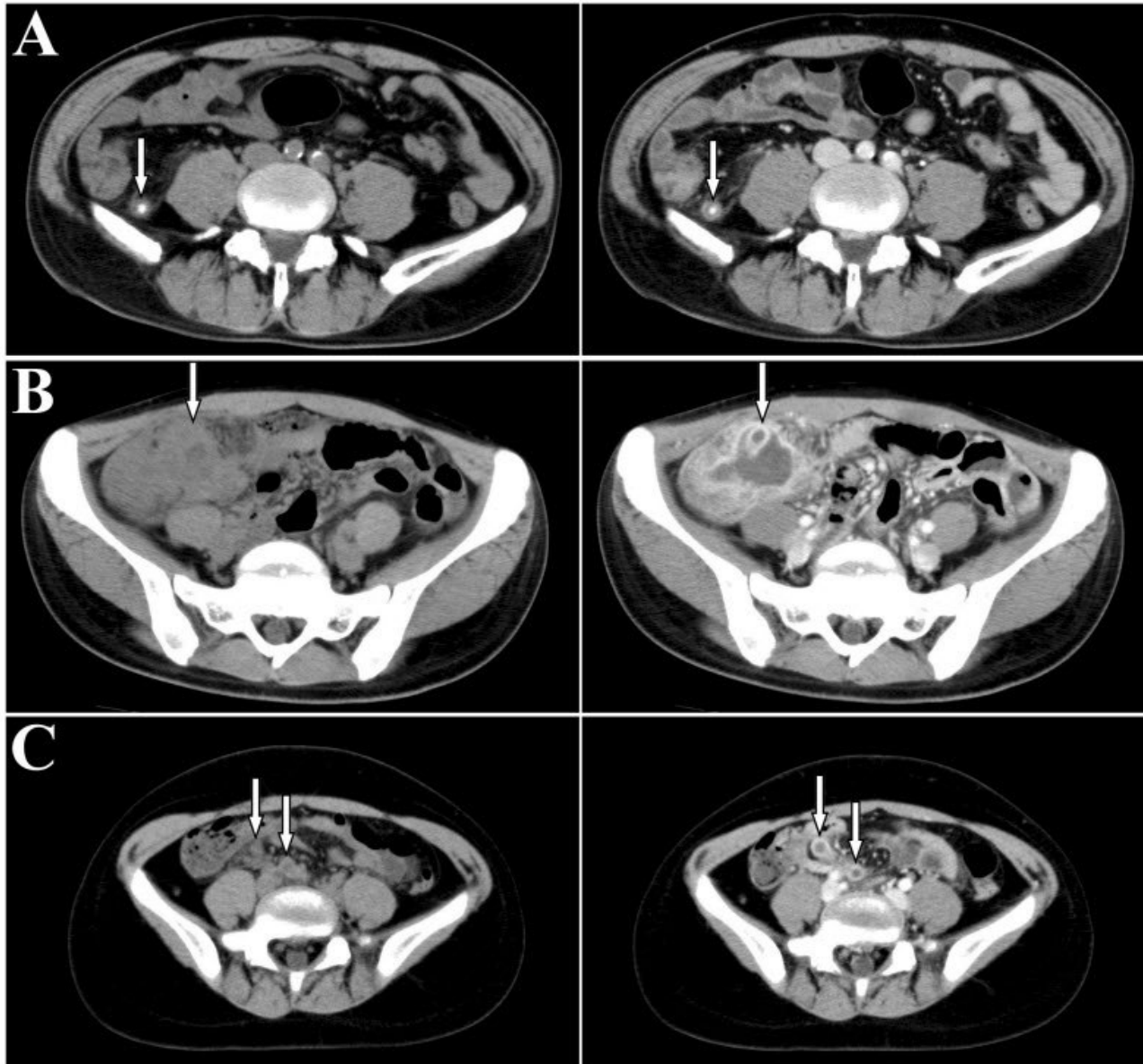


Figure 1: Representative images indicating appendicitis on noncontrast and enhanced CT. (A) A 62-year-old male with phlegmonous appendicitis. A fecalith and appendiceal wall thickening were detected on noncontrast and enhanced CT as indicated by an arrow. (B) A 31-year-old female with gangrenous appendicitis. Abscess formation was clearly detected on enhanced CT as indicated by an arrow. (C) A 8-year-old girl with phlegmonous appendicitis. Detection of vermiform appendix was difficult on noncontrast CT, whereas enlarged appendix with appendiceal wall thickening was clearly detected on enhanced CT as indicated by arrows.

Patient characteristics	(A) Number of patients	Appendix			Fecalith	(B) Appendicitis diagnosed# (B/A, %)	(C) Appendectomy performed (C/B, %)
		Thickening	Normal	Undetected			
0-15 years old							
Male	32	17 (53.1%)	7 (21.9%)	8 (25.0%)	9 (28.1%)	26 (81.3%)	21 (80.8%)
Female	14	8 (57.2%)	1 (7.1%)	5 (35.7%)	6 (42.9%)	13 (92.9%)	10 (76.9%)
>15 years old							
Male	111	93 (83.8%)	11 (9.9%)	7 (6.3%)*	37 (33.3%)	100 (90.1%)	92 (92.0%)
Female	90	56 (62.2%)	14 (15.6%)	20 (22.2%)	27 (30.0%)	71 (78.9%)	59 (83.1%)
Total	247	174 (70.4%)	33 (13.4%)	40 (16.2%)	79 (32.0%)	210 (85.0%)	182 (86.7%)

Table 1: CT findings in patients who underwent noncontrast or combined noncontrast and enhanced CT examination on clinically suspected appendicitis.

*The detection rate of vermiform appendix was significantly higher in adult male patients than that in the other patient groups (p<0.05). #The final clinical diagnosis.

Patient characteristics	(A) Number of patients	(B) Noncontrast CT alone performed#	(C) Noncontrast and enhanced CT performed##	(D) Among C, diagnosis could be made on noncontrast CT (D/C, %)	(E) Among C, enhanced CT was required for the final diagnosis (E/C, %)	(F)
						P value*
0-15 years old						
Male	21	10	11	7 (63.6%)	4 (36.4%)	0.037
Female	9	2	7	4 (57.1%)	3 (42.9%)	0.051
>15 years old						
Male	96	38	58	49 (84.5%)	9 (15.5%)	0.243 [†]
Female	59	23	36	26 (72.2%)	10 (27.8%)	0.004
Total	185	73	112	86 (76.8%)	26 (23.2%)	<0.001

Table 2: Detection of vermiform appendix on noncontrast and enhanced CT in patients with the final diagnosis of appendicitis. The patients (185 cases) who were diagnosed to have acute appendicitis with appendiceal thickening (167 cases) or normal-sized appendix (18 cases) were analyzed.

#The number of patients, who underwent noncontrast CT alone. ##The number of patients, who underwent noncontrast CT followed by enhanced CT with intravenous contrast material. *The p value in each group was calculated to determine whether the number shown in column E was significantly different from the value of 10% of the number shown in column C (the statistical analysis for the rate). In this case, the significant difference (p<0.05) indicates that enhanced CT is required to obtain the final diagnosis in at least 10 cases among 100 patients with acute appendicitis. The p value in the group of adult male patients was <0.05 when the number shown in column E was compared with the value of 5% of the number shown in column C, indicating that enhanced CT is required to obtain the final diagnosis in at least 5 cases among 100 adult male patients with acute appendicitis. The values of 5-10% may be clinically significant, and the significant difference may support the notion that enhanced CT is superior to noncontrast CT to obtain the final diagnosis of acute appendicitis.

Patient characteristics	Number of patients	Appendicitis				Normal
		Catarrhal	Phlegmonous	Gangrenous	Chronic	
0-15 years old						
Male	21	1	18	2	0	0
Female	10	0	6	4	0	0
>15 years old						
Male	92	11	52	24	1	4
Female	59	10	30	15	0	4
Total	182	22	106	45	1	8

Table 3: Pathological reports of removed appendices.

ABBREVIATIONS

CT = Computed tomography
 MRI = Magnetic resonance imaging

KEYWORDS

Computed tomography, appendicitis

ACKNOWLEDGEMENTS

We thank Dr. M. Fukui, Laboratory of Statistics, Osaka City University Medical School, for kind help for the statistical analysis.

Online access

This publication is online available at:
www.radiologycases.com/index.php/radiologycases/article/view/101

Interactivity

This publication is available as an interactive article with scroll, window/level, magnify and more features.
 Available online at www.RadiologyCases.com

Published by EduRad



www.EduRad.org