

Retroperitoneal Fibrosis as a Cause of Positive FDG PET/CT

Amar Mehta¹, Todd M. Blodgett^{2*}

1. Department of Radiology, University of Pittsburgh, Pittsburgh, PA, USA

2. Foundation Radiology Group, Pittsburgh, PA, USA

* **Correspondence:** Todd Blodgett, M.D., Foundation Radiology Group, Address: 401 Liberty Avenue, Suite 2000, Three Gateway Center, 20th Floor, Pittsburgh, PA 15222, USA
(✉ toddblodgett@yahoo.com)

Radiology Case. 2011 July; 5(7):35-41 :: DOI: 10.3941/jrcr.v5i7.722

ABSTRACT

This article educates the reader on idiopathic retroperitoneal fibrosis and emphasizes the importance of considering conditions that mimic this disease on PET/CT through an illustrative case of a 58 year-old man presenting with intermittent abdominal, back, and scrotal pain undergoing successive PET/CT scans, both for diagnosis and following treatment.

CASE REPORT

CASE REPORT

This is a case of a 58 year-old man who presented with approximately two weeks of intermittent abdominal, left lower back, and left scrotal pain. The patient was initially evaluated with a CT scan of the abdomen and pelvis, which showed circumferential soft-tissue thickening primarily around the left common iliac artery and vein causing minimal external compression of the vessels. The scan was also significant for left-sided hydronephrosis and slight medial deviation of the left ureter, for which the patient was treated with insertion of a double-J ureteral stent. Biopsy taken at this time showed dense fibrous tissue containing lymphocytes, plasma cells, neutrophils and eosinophils, findings which, though supporting the clinical impression of retroperitoneal fibrosis, were deemed non-specific; malignancy could not entirely be ruled out, though biopsy showed no evidence of neoplasm. The patient was prescribed steroids for approximately three months with resolution of his symptoms.

The patient was referred for an initial PET/CT scan in July of 2008 to evaluate for potential lymphoma (Figure 1). This study showed diffuse moderate FDG activity corresponding to the CT soft tissue abnormality also found on CT scan 1 month prior. A follow-up PET/CT scan performed 3 months later (4 months after onset of symptoms) demonstrated progression of the soft-tissue infiltration with

involvement of the distal aorta and right common iliac vessels (Figure 2). The metabolic activity within the soft tissue also increased slightly with a SUVmax of 5.9 compared to the initial scan SUVmax of 3.2.

The characteristic extension of the mass, the pattern of FDG uptake, and lack of lymph node involvement led to interpretation of the scan as suspicious for retroperitoneal fibrosis and less likely as lymphoma. The patient was placed on steroids for 3 months, when a third PET/CT scan was performed (Figure 3), demonstrating complete resolution of the soft tissue infiltration around the aorta and iliac vessels and complete resolution of the abnormal FDG activity.

DISCUSSION

Retroperitoneal fibrosis (RPF) is a rare condition characterized by chronic inflammatory tissue with appreciable fibrosis in the retroperitoneum which can expand to entrap various abdominal organs. The inflammatory component consists of lymphocytes, plasma cells, macrophages, and scattered eosinophils, while fibroblasts and myofibroblasts compose a sclerotic matrix of type I collagen (1). Though the true incidence of RPF is unknown, estimates range from 1 in 200,000 to 500,000 (2, 3). The condition occurs in men two

to three times as much as in women, and peak incidence occurs in patients between 40 to 60 years of age (4-6). However, at least 23 cases have been reported in children under 18 (7). Over two-thirds of RPF cases are considered idiopathic, and though its etiology remains unclear, it is thought to involve an immune-mediated response to severe atherosclerosis (1, 5). One third of cases of RPF occur secondary to other causes including neoplasms, infections, hemorrhage, trauma, radiotherapy, surgery, and use of certain drugs (8, 9). There is no evidence of an ethnic predilection or a familial pattern of this disease.

Patients typically present with insidious dull abdominal, lumbar, back or flank pain that becomes acute and colicky with ureteral involvement. Constitutional and non-specific GI symptoms are common, as is scrotal pathology (swelling, pain, hydrocele, varicocele) and finally deep vein thrombosis (1, 10, 11). Physical examination is generally unremarkable with the exception of hypertension, probably of renal origin. Due to non-specific findings, patients can present in renal failure secondary to obstructive uropathy and long-standing hydronephrosis before the correct diagnosis is made (11)(12). Ureteral involvement is reported in 80 - 100% of cases (12), and indeed the late stage of RPF is characterized by progressive ureteral obstruction, bilateral reportedly in over half of RPF cases (13, 14). Diagnosis usually depends on radiographic evaluation, CT and MRI being the modalities of choice (see later). Retroperitoneal biopsy is usually performed only in cases with atypical localizations or when clinical or laboratory findings suggest an underlying infection or malignancy (1).

Primary retroperitoneal neoplasms, such as lymphoma or sarcoma, and metastatic retroperitoneal tumors, such as breast and colon carcinomas, can also produce a desmoplastic reaction and thus mimic RPF (1). There are several case reports in the literature concerning the similar appearance of lymphoma and idiopathic RPF on CT and MRI (15-18); however, to our knowledge, the PET/CT findings of retroperitoneal fibrosis have been described in only one other case (19). Differentiating between lymphoma and RPF remains crucial, as implications for treatment differ drastically. Similarly, wherever retroperitoneal fibrosis is suspected, it is important to discern idiopathic from secondary forms of RPF, again due to treatment implications. Of particular importance is RPF secondary to malignancy, which is caused by infiltration of the retroperitoneum by malignant cells producing a pronounced desmoplastic and sclerotic reaction. Malignant RPF is estimated to account for 8% of cases of RPF (5). Due to the poor prognosis of malignant RPF (20), an appreciation for its potential and an appreciation of the radiographic features are vital to the assessment of affected patients. By contrast, cases of idiopathic RPF portend a very favorable prognosis, though relapse is common after withdrawal of glucocorticoids, even several years after treatment, and therefore requires close monitoring (1).

As mentioned previously, diagnosis relies heavily on imaging. CT characteristically shows a paraspinal, well-demarcated retroperitoneal mass of varying thickness with irregular borders, isodense with muscle (21). It most

commonly surrounds the anterior and lateral sides of the abdominal aorta and iliac arteries, often appearing at the level of L4-L5, spreading cranially towards the renal hila (1, 10). Ureteral encasement, medial deviation, and obstruction are frequent sequelae, and other abdominal structures such as the IVC can similarly become enveloped by the retroperitoneal mass (1, 8, 10). The mass shows pronounced enhancement with contrast, a finding that varies with activity of the fibrotic process; that is, in early stages of the disease, contrast enhancement is striking, though in a chronic, advanced setting, little or no enhancement may be seen (1, 21). Similar to other fibrotic processes, RPF manifests as a hypointensity on T1-weighted images. T2 signal, however, again varies with degree of disease activity, reflected by inflammation and edema. Chronic, inactive fibrosis will contain little edema and thus displays low-intensity signal on both T1 and T2. PET imaging has emerged as potentially useful in diagnosis, shown in a recent small study to correlate with mass thickness and CRP levels, though proper interpretation of increased FDG uptake in most clinical situations associated with RPF remains unclear (1, 22, 23). Additionally, several authors have also recently described the relevance of FDG PET in monitoring response to corticosteroid therapy in cases of RPF, with diminishing avidity correlating with decreases in inflammatory markers and subsequent increased radiotracer uptake signalling relapse of disease activity (21, 23, 24).

Characterizing differentiating features of idiopathic RPF from underlying malignancy by radiographic evidence has proven challenging. However, several findings that have been described to support the malignant RPF include a more cephalad distribution of a larger, bulkier mass, more likely to display mass effect, pushing the aorta and IVC anteriorly and the ureters laterally (25, 26). Finally, underlying lymphoma tends to be homogenous and hypovascular with less contrast enhancement on CT, is associated with lymphadenopathy, and shows speckled enhancement on T1, relatively lower intensity signal on T2, and delayed enhancement on dynamic MR (27, 28). It is important to note that in cases of lymphoma, PET often has discrete FDG avid nodes, but can also atypically appear as a diffuse soft tissue mantle, mimicking the findings of RPF.

In conclusion, upon suspicion of idiopathic retroperitoneal fibrosis, one must be cognizant that the imaging findings of this process are often mimicked by lymphoma and by RPF due to secondary causes, malignancy in particular. These entities must be ruled out before the diagnosis is made.

TEACHING POINT

In patients undergoing PET/CT evaluation for suspected lymphoma, particularly those that display imaging characteristics such as pronounced enhancement, non-bulky nature, and periaortic location, retroperitoneal fibrosis should be entertained as a potential diagnosis, as this process may mimic other imaging findings of neoplastic disease.

REFERENCES

- Vaglio A, Palmisano A, Corradi D, Salvarani C, Buzio C. Retroperitoneal fibrosis: evolving concepts. *Rheum Dis Clin North Am*. 2007;33(4):803-17, vi-vii. PMID: 18037118.
- Kottra JJ, Dunnick NR. Retroperitoneal fibrosis. *Radiol Clin North Am*. 1996;34(6):1259-75. PMID: 8898793.
- Higgins PM, Bennett-Jones DN, Naish PF, Aber GM. Non-operative management of retroperitoneal fibrosis. *Br J Surg*. 1988;75(6):573-7. PMID: 3293696.
- van Bommel EF, van Spengler J, van der Hoven B, Kramer P. Retroperitoneal fibrosis: report of 12 cases and a review of the literature. *Neth J Med*. 1991;39(5-6):338-45. PMID: 1803245.
- Lepor H, Walsh PC. Idiopathic retroperitoneal fibrosis. *J Urol*. 1979;122(1):1-6. PMID: 379367.
- Gilkeson GS, Allen NB. Retroperitoneal fibrosis. A true connective tissue disease. *Rheum Dis Clin North Am*. 1996;22(1):23-38. PMID: 8907063.
- Miller OF, Smith LJ, Ferrara EX, McAleer IM, Kaplan GW. Presentation of idiopathic retroperitoneal fibrosis in the pediatric population. *J Pediatr Surg*. 2003;38(11):1685-8. PMID: 14614727.
- Vaglio A, Salvarani C, Buzio C. Retroperitoneal fibrosis. *Lancet*. 2006;367(9506):241-51. PMID: 16427494.
- Koep L, Zuidema GD. The clinical significance of retroperitoneal fibrosis. *Surgery*. 1977;81(3):250-7. PMID: 841463.
- Heckmann M, Uder M, Kuefner MA, Heinrich MC. Ormond's disease or secondary retroperitoneal fibrosis? An overview of retroperitoneal fibrosis. *Rofo*. 2009;181(4):317-23. PMID: 19291600.
- van Bommel EF. Retroperitoneal fibrosis. *Neth J Med*. 2002;60(6):231-42. PMID: 12365466.
- Baker LR, Mallinson WJ, Gregory MC, Menzies EA, Cattell WR, Whitfield HN, et al. Idiopathic retroperitoneal fibrosis. A retrospective analysis of 60 cases. *Br J Urol*. 1987;60(6):497-503. PMID: 3427331.
- Kardar AH, Kattan S, Lindstedt E, Hanash K. Steroid therapy for idiopathic retroperitoneal fibrosis: dose and duration. *J Urol*. 2002;168(2):550-5. PMID: 12131307.
- van Bommel EF, Siemes C, Hak LE, van der Veer SJ, Hendriks TR. Long-term renal and patient outcome in idiopathic retroperitoneal fibrosis treated with prednisone. *Am J Kidney Dis*. 2007;49(5):615-25. PMID: 17472843.
- Sterzer SK, Herr HW, Mintz I. Idiopathic retroperitoneal fibrosis misinterpreted as lymphoma by computed tomography. *J Urol*. 1979;122(3):405-6. PMID: 470023.
- Milcent K, Franchi-Abella S, Larrar S, Guitton C, Valteau-Couanet D, Kone-Paut I, et al. [Retroperitoneal fibrosis and lymphoma in a 15-year-old boy]. *Arch Pediatr*. 2008;15(12):1756-9. PMID: 18976891.
- Tuinman PR, de Nes LC, Blaauwgeers JL, Koene HR, Peters SH, Hart W. [Clinical reasoning and decision-making in practice. A man with hip pain and fever]. *Ned Tijdschr Geneesk*. 2008;152(28):1560-7. PMID: 18712223.
- Chim CS, Liang R, Chan AC. Sclerosing malignant lymphoma mimicking idiopathic retroperitoneal fibrosis: importance of clonality study. *Am J Med*. 2001;111(3):240-1. PMID: 11545095.
- Nakajo M, Jinnouchi S, Noguchi M, Uozumi K, Tanabe H, Tateno R. FDG PET and PET/CT monitoring of autoimmune pancreatitis associated with extrapancreatic autoimmune disease. *Clin Nucl Med*. 2007;32(4):282-5. PMID: 17413574.
- Arrive L, Hricak H, Tavares NJ, Miller TR. Malignant versus nonmalignant retroperitoneal fibrosis: differentiation with MR imaging. *Radiology*. 1989;172(1):139-43. PMID: 2740497.
- Cronin CG, Lohan DG, Blake MA, Roche C, McCarthy P, Murphy JM. Retroperitoneal fibrosis: a review of clinical features and imaging findings. *AJR Am J Roentgenol*. 2008;191(2):423-31. PMID: 18647912.
- Nakajo M, Jinnouchi S, Tanabe H, Tateno R. 18F-fluorodeoxyglucose positron emission tomography features of idiopathic retroperitoneal fibrosis. *J Comput Assist Tomogr*. 2007;31(4):539-43. PMID: 17882028.
- Jansen I, Hendriks TR, Han SH, Huiskes AW, van Bommel EF. (18)F-fluorodeoxyglucose position emission tomography (FDG-PET) for monitoring disease activity and treatment response in idiopathic retroperitoneal fibrosis. *Eur J Intern Med*. 2007;21(3):216-21. PMID: 20493425.
- Young PM, Peterson JJ, Calamia KT. Hypermetabolic activity in patients with active retroperitoneal fibrosis on F-18 FDG PET: report of three cases. *Ann Nucl Med*. 2008;22(1):87-92. PMID: 18250993.
- Amis ES, Jr. Retroperitoneal fibrosis. *AJR Am J Roentgenol*. 1991;157(2):321-9. PMID: 1853816.
- Brun B, Laursen K, Sorensen IN, Lorentzen JE, Kristensen JK. CT in retroperitoneal fibrosis. *AJR Am J Roentgenol*. 1981;137(3):535-8. PMID: 6974466.
- Nishino M, Hayakawa K, Minami M, Yamamoto A, Ueda H, Takasu K. Primary retroperitoneal neoplasms: CT and MR imaging findings with anatomic and pathologic diagnostic clues. *Radiographics*. 2003;23(1):45-57. PMID: 12533639.

28. Nishimura H, Zhang Y, Ohkuma K, Uchida M, Hayabuchi N, Sun S. MR imaging of soft-tissue masses of the extraperitoneal spaces. Radiographics. 2001;21(5):1141-54. PMID: 11553822.

29. Elsayes KM, Staveteig PT, Narra VR, Chen ZM, Moustafa YL, Brown J. Retroperitoneal masses: magnetic resonance imaging findings with pathologic correlation. Curr Probl Diagn Radiol. 2007;36(3):97-106. PMID: 17484953.

FIGURES

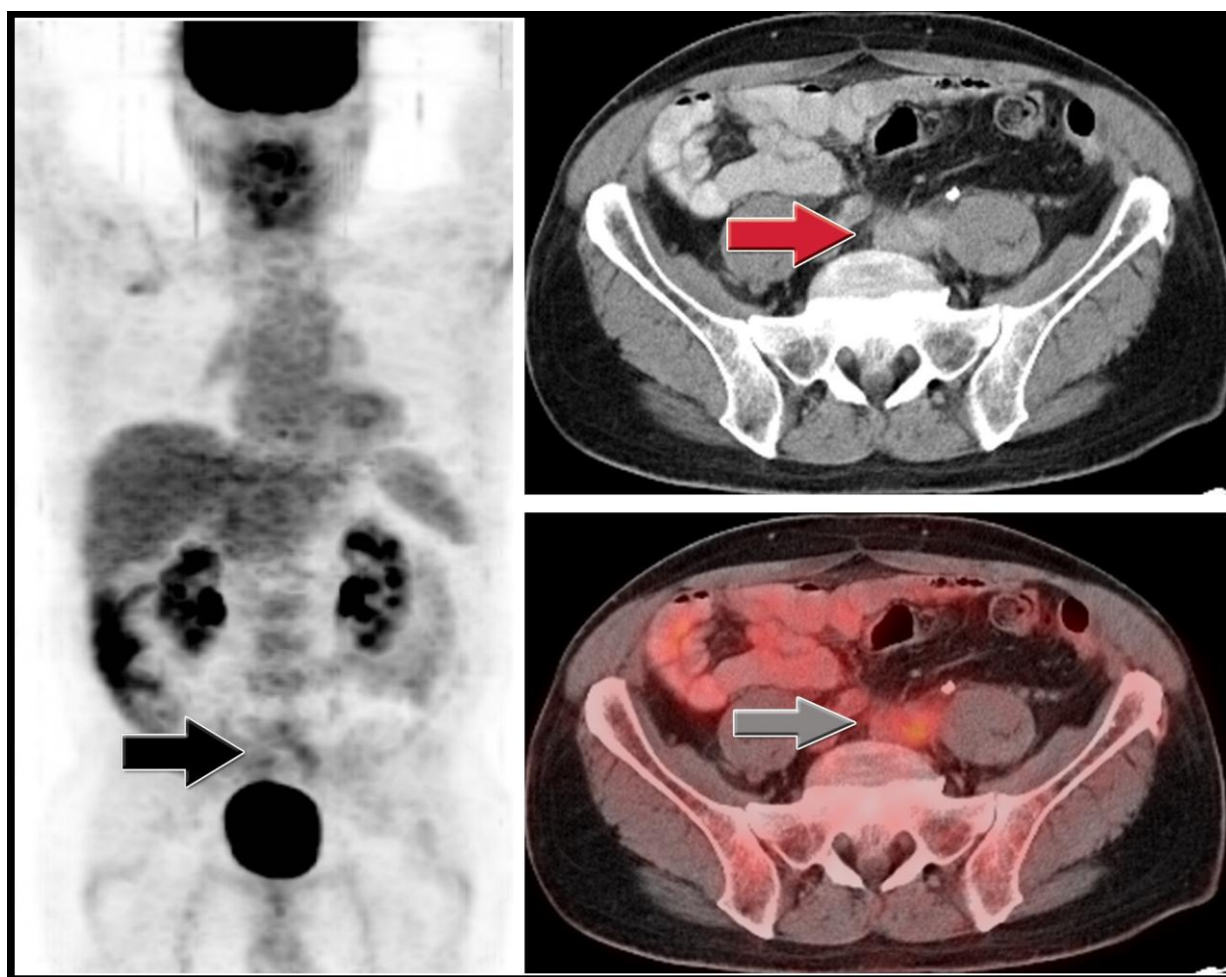


Figure 1: (left) PET coronal, (upper right) CT axial, and (lower right) PET/CT axial views of a 58 year-old man with (unknown) retroperitoneal fibrosis, undergoing initial PET/CT to evaluate for potential lymphoma. Diffuse moderate FDG activity corresponding to CT soft tissue abnormality is seen as an infiltrative soft tissue mass surrounding left common iliac artery and vein causing minimal compression of the vessels. (Performed 60 minutes after injection of FDG tracer, dose of 17.53 mCi, with 5 mm slice thickness, CT-based attenuation correction algorithm using two iterations and 8 subsets, 120 kVp, 112 mAs.)

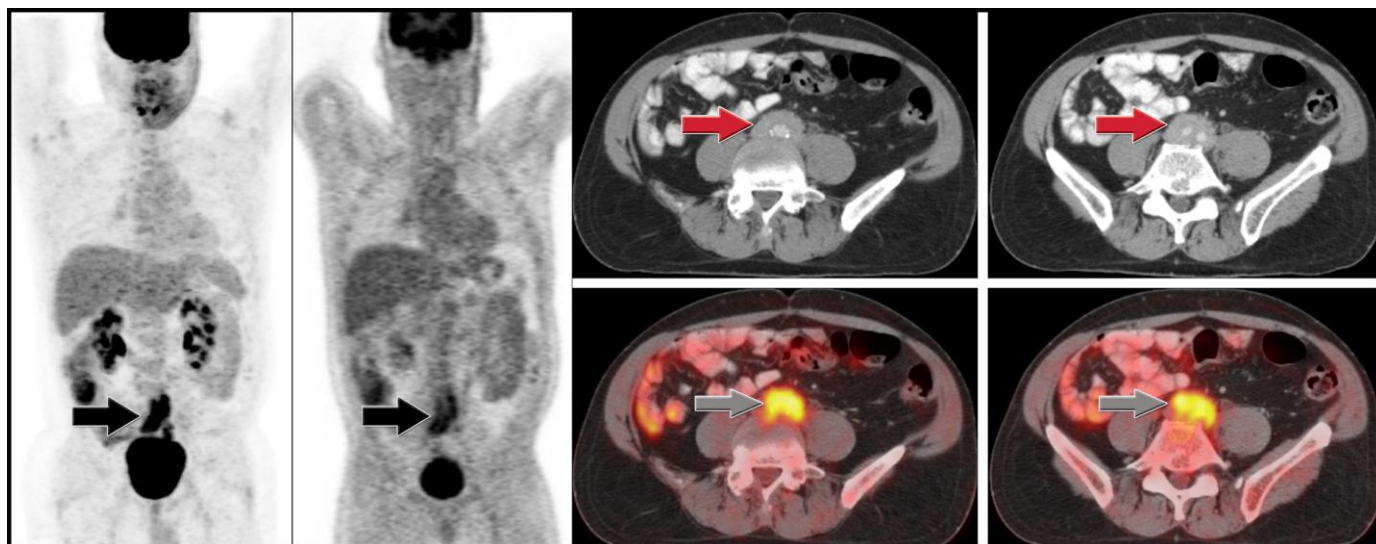


Figure 2: (left) PET coronal, (upper right) CT axial, and (lower right) PET/CT axial views of a 58 year-old man with retroperitoneal fibrosis at diagnosis. Seen is circumferential soft-tissue thickening around the distal aorta and common iliac vessels, as well as associated diffuse moderate FDG activity within the soft tissue. (Performed 60 minutes after injection of FDG tracer, dose of 17.2 mCi, with 5 mm slice thickness, CT-based attenuation correction algorithm using two iterations and 8 subsets, 120 kVp, 280 mAs.)

Journal of Radiology Case Reports

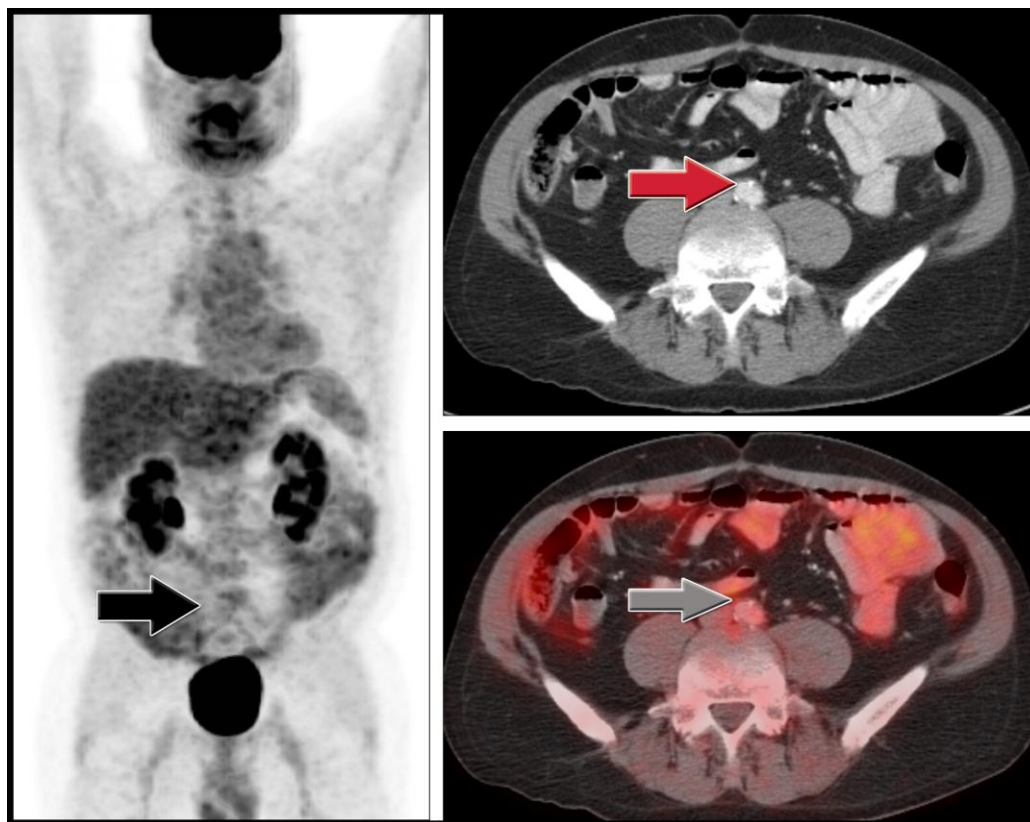


Figure 3: (left) PET coronal, (upper right) CT axial, and (lower right) PET/CT axial views of a 58 year-old man with retroperitoneal fibrosis following steroid therapy. There is complete resolution of the soft tissue infiltration around the aorta and iliac vessels and complete resolution of the abnormal FDG activity. (Performed 60 minutes after injection of FDG tracer, dose of 16.7 mCi, with 5 mm slice thickness, CT-based attenuation correction algorithm using two iterations and 8 subsets, 120 kVp, 294 mAs.)

www.RadiologyCases.com

Etiology	2/3 idiopathic OR 1/3 secondary to neoplasms, infections, hemorrhage, trauma, radiotherapy, surgery, use of certain drugs
Incidence	1 in 200,000 – 500,000
Gender Ratio	2-3 M : 1 F
Age Predilection	Peak incidence 40 – 60 years old
Risk Factors	Severe atherosclerosis, neoplasms, infections, hemorrhage, trauma, radiotherapy, surgery, and use of certain drugs
Treatment	Steroid therapy; address underlying cause; treat sequelae (e.g. hydronephrosis – relieve ureteral obstruction)
Prognosis	Very good prognosis in idiopathic RPF, though high relapse rate; poor prognosis in cases of malignant RPF
Findings on imaging	Modality of choice: CT or MRI
<u>CT:</u>	<ul style="list-style-type: none"> • Periaortic mass, usually around the anterior and lateral sides of the abdominal aorta; • Often causes medial deviation and extrinsic compression of the ureters • Craniocaudal extension from the origin of the renal arteries to the common iliac vessels, but may also involve the superior mesenteric artery or the internal and external iliac vessels • IVC often encased and compressed • Isodense to muscle • Pronounced enhancement with contrast, particularly in early disease stages(1) • on T1-weighted images • Variable signal on T2-weighted images - hyperintense when active inflammation is present and hypointense in end-stage fibrosis(29)
<u>MRI:</u>	Hypointense on T1 and T2 weighted sequences

Table 1: Summary table for retroperitoneal fibrosis

	CT	MRI	PET
Retroperitoneal Fibrosis	<ul style="list-style-type: none"> • Periaortic mass, usually around the anterior and lateral sides of the abdominal aorta • Often causes medial deviation and extrinsic compression of the ureters • Craniocaudal extension from the origin of the renal arteries to the common iliac vessels, but may also involve the superior mesenteric artery or the internal and external iliac vessels • IVC often encased and compressed • Isodense to muscle • Pronounced enhancement with contrast, particularly in early disease stages(1) 	<ul style="list-style-type: none"> • Hypointensity • on T1-weighted images • Variable signal on T2-weighted images - hyperintense when active inflammation is present and hypointense in end-stage fibrosis(29) 	<ul style="list-style-type: none"> • Has emerged as potentially useful, though proper interpretation of increased FDG • uptake in most clinical situations associated with RPF remains unclear(1)
Lymphoma	<ul style="list-style-type: none"> • Tend to be homogenous and hypovascular with minimal contrast enhancement • Associated lymphadenopathy • Tends to surround adjacent vessels, manifesting with the “floating aorta sign”(27) 	<ul style="list-style-type: none"> • Speckled enhancement on T1-weighted images • Relatively low signal intensity at T2-weighted MR imaging • Delayed enhancement on dynamic MR(27, 28) 	<ul style="list-style-type: none"> • Oftentimes has discrete nodes; however can atypically appear as diffuse soft tissue mantle, mimicking findings of RPF

Table 2: Differential diagnosis table for retroperitoneal fibrosis

ABBREVIATIONS

CT - Computed Tomography
 FDG - Fluorodeoxyglucose
 RPF - Retroperitoneal Fibrosis
 SUVmax - Standardized uptake value (maximum value)

KEYWORDS

FDG PET; PET/CT; retroperitoneal fibrosis; lymphoma

Online access

This publication is online available at:
www.radiologycases.com/index.php/radiologycases/article/view/722

Peer discussion

Discuss this manuscript in our protected discussion forum at:
www.radiolopolis.com/forums/JRCR

Interactivity

This publication is available as an interactive article with scroll, window/level, magnify and more features.
 Available online at www.RadiologyCases.com

Published by EduRad



www.EduRad.org