

Epiploic Appendagitis in a Female Patient with Situs Ambiguus Abnormality

Christopher Ryen^{1*}

1. Kansas City University of Medicine and Biosciences, Kansas City, MO, USA

* **Correspondence:** Christopher Ryen, 2000 S. Berkshire, Springfield, MO 65809, USA
(✉ Chrisryen@hotmail.com)

Radiology Case. 2009 Aug; 3(8):30-34: DOI: 10.3941/jrcr.v3i8.282

ABSTRACT

We report the case of a 23 year-old obese female, with previously diagnosed situs inversus below the diaphragm, who presented with severe left upper quadrant abdominal pain. The patient was believed to have a surgical indication, possibly appendicitis or diverticulitis, and had an emergent abdominal Computed Tomography (CT) scan. The CT was interpreted as epiploic appendagitis with no signs of appendicitis. Epiploic appendagitis is a rare cause of acute abdominal pain, which involves the torsion and eventual necrosis of one of the epiploic appendages. This case was complicated by the fact that the patient had situs inversus below the diaphragm, which made it difficult to relate her localized abdominal pain to the correct anatomic area. The diagnosis allowed the patient to avoid invasive surgery and instead opt for conservative medical management. The utilization of radiologic imaging is of utmost importance in diagnosing this condition, which has characteristic findings on CT, US, and MR, all of which is discussed in this article.

CASE REPORT

CASE REPORT

A 23 year-old obese Caucasian female presented to the emergency department with acute onset left upper quadrant pain. The patient described her pain as a constant, sharp, non-radiating pain with 8/10 severity. She was afebrile and denied symptoms of nausea, vomiting, constipation, or diarrhea.

Her past medical history was significant for situs inversus without dextrocardia. Past surgical history was significant for surgical correction of a bowel obstruction at 5 days of age, which resulted in an incidental appendectomy.

All of her vitals signs were within normal limits. The only lab value of significance was a slightly elevated WBC count of 15.16×10^3 upon hospital admission, which quickly decreased to normal limits. A surgical abdomen could not be ruled out at this time without radiological imaging and the patient was sent for a CT scan.

An abdominopelvic CT scan with IV and rectal contrast revealed situs abnormalities described as situs ambiguus with polysplenia. Multiple spleens were identified, the stomach was located in the right upper quadrant, and the liver spanned large portions on both sides of the midline. It was noted that the majority of the colon, including the sigmoid colon, was in the right abdomen and the majority of the small bowel loops were in the left abdomen (Figure 1). Most suspicious was the focal wall thickening of the transverse colon of 2 cm with inflammation surrounding a fatty lesion of 2.8 x 0.8 cm in the left upper abdomen, indicating epiploic appendagitis (Figure 2, 3).

The CT findings were not consistent with an acute abdomen requiring surgical intervention as was originally suspected. The diagnosis of epiploic appendagitis completely altered the treatment plan because it was ruled that the patient could be treated medically instead of surgically. Conservative

treatment is the first choice and the patient was commenced ibuprofen 600 mg every six hours.

DISCUSSION

The colon has many fat-filled outpouchings that project into the peritoneal cavity that are referred to as epiploic appendages, epiploic appendices, appendix epiploica, or appendices epiploicae. There are usually 50-100 of these structures that are in anterior and posterior rows parallel to the taenia coli of the colon (1). Each epiploic appendage has a vascular stalk that attaches it to the wall of the colon and which contains a branch of the circular artery and vein that supplies the underlying area of colon.

These structures may vary greatly in their size and shape. The average length of an appendage is 3 cm, with most in the range of 0.5-5.0 cm; however, they may be as long as 15 cm (1, 2). Although the function of these structures is unknown, they may act as a bacteriostatic protection mechanism similar to the greater omentum. They may also function to protect the blood supply of the colon when it is collapsed or may play a role in colonic absorption (3, 4).

Epiploic appendagitis is a disorder in which the appendage has torsion on itself along its long axis. Torsion, stretching, or kinking of these structures may compromise the vascular supply and can cause ischemia, thrombosis, infarction and eventually gangrenous necrosis (1). This necrosis may sometimes be hemorrhagic (1). It is also possible, yet very unlikely, that a primary thrombosis may occur in a vessel that has not suffered any torsion. In an acute case, the patient may experience a great deal of pain that is specifically localized. When the torsion and infarction occurs insidiously, the patient does not usually experience the same level of pain and no treatment may be sought.

Many cases of epiploic appendagitis are diagnosed during surgery. The surgeon may be looking for an inflamed appendix or diverticulum, and then spot a necrotic epiploic appendage. Ideally, the diagnosis may be made early and surgery can be avoided altogether. Diagnosis is usually made by a history and physical examination in combination with a contrast CT scan. CT has been supported for diagnosing epiploic appendagitis in recent reports (5, 6).

Many clues on physical examination may be important in working up acute abdominal pain. Epiploic appendagitis, like appendicitis and diverticulitis, usually presents with a sharp and localized pain in the lower abdomen. It has been reported that epiploic appendagitis may be expected to be found in nearly 1% of patients who were suspected to have an acute appendicitis case (7). In contrast with diverticulitis and appendicitis, patients with epiploic appendagitis usually are afebrile, without any leukocytosis, and without any complaints of nausea or vomiting.

While these physical examination findings are important, a contrast CT scan is necessary for a definitive diagnosis of epiploic appendagitis. Past cases of epiploic appendagitis were mostly diagnosed on surgical exploration for a different cause of acute abdominal pain. Currently, radiologic imaging plays a key role in the diagnosis of epiploic appendagitis. Normal epiploic appendages are adipose structures that have fat

attenuation on CT and in normal cases cannot be distinguished from retroperitoneal fat. However, if these structures have inflammation or surrounding intraperitoneal fluid, as in the case of epiploic appendagitis, they may then be visualized on CT (1).

There have been many CT findings that are considered pathognomonic for epiploic appendagitis; included is a fat attenuated oval mass less than 5 cm diameter (usually 1.5-4 cm) in size abutting the anterior colonic wall, which is surrounded by a ring of inflammatory changes (1, 6). A helpful finding of epiploic appendagitis, which is not always present, is a central high-attenuation focus inside the fat (6). This central focus might represent a venous occlusion due to vessel thrombosis within the epiploic appendage (6). In some cases, a thickening of the parietal peritoneum wall occurs due to the spread of inflammation (1, 8).

CT may show characteristic findings for epiploic appendagitis that can distinguish it from appendicitis or diverticulitis. The CT should also differentiate this diagnosis from acute appendicitis or diverticulitis by the absence of CT findings important for their diagnosis. For example, CT will show a normal appendix without signs of the presence of an appendicolith, fluid-filled appendix, or a dilated or thickened wall (9). CT would also be inconsistent with the characteristic findings in diverticulitis, including the presence of a diverticulum, inflammatory thickening of the colon wall or muscular wall hypertrophy (10). Unlike in diverticulitis, which shows thickening of the colon wall on CT, epiploic appendagitis usually shows normal thickness of the colon wall; however, in this case there was colonic wall thickening present (6).

Other imaging modalities can also be utilized in the diagnosis of epiploic appendagitis. Ultrasonography (US) imaging may be obtained at the point of maximal tenderness. The typical US findings are those of a non-compressible mass adjacent to the colon that is fixed in position. The mass is hyperechoic, well-defined, and usually has a hyperechoic rim (11, 12). Zones within the mass that are hypoechoic might also be observed as well as lack of change of the colon wall (12). Color Doppler US imaging of epiploic appendagitis is avascular and shows no central blood flow (11, 12). Pericolonic fatty tissue changes that may occur with acute diverticulitis can therefore be distinguished from epiploic appendagitis, which has an absence of color Doppler signal (12).

Epiploic appendagitis has rarely been diagnosed on magnetic resonance (MR) imaging. A focal fat signal intensity may be seen on either T1 or T2-weighted MR imaging (13). When using T1-weighted fat suppressed MR images enhanced with gadolinium, the fat attenuated lesions of epiploic appendagitis show an enhancing rim encircling the lesion due to inflammation (13).

This case is unique because the patient had a previous diagnosis of situs inversus, which made the diagnosis much more difficult. After reviewing the CT scan, the patient was diagnosed as having situs ambiguous abnormality with polysplenia (Figure 4). Her liver had large portions located in the left and right upper quadrants, the majority of the colon located in the right abdomen, the stomach located in the right abdomen, and multiple spleens seen clearly on CT image.

The term situs describes the position of the viscera in relationship to the midline of the body. Situs solitus is the term

given to the normal positioned viscera, whereas situs inversus indicates an anatomic positioning that is a mirror image of situs solitus. Situs ambiguous, or heterotaxy, which is present in this case, is an abnormal anatomic arrangement of the intraabdominal organs and vessels, where they are in ambiguous locations (14). There are two main variants including situs ambiguous with asplenia and situs ambiguous with polysplenia.

The estimated incidence of situs abnormalities is 1 case per 10,000 live births for situs inversus and 0.25 cases per 10,000 live births for situs ambiguous (15, 16). These situs abnormalities are often associated with congenital heart disease. Situs inversus patients have a congenital heart disease incidence of 3-5%, whereas situs ambiguous patients have a congenital heart anomaly incidence of 90-99% (17, 18). Mortality rates in situs ambiguous are very high with 60% of situs ambiguous patients with polysplenia not surviving their first year (19).

Most cases of epiploic appendagitis occur on the sigmoid colon (8), which may be due to the fact that epiploic appendages are most commonly found in the sigmoid colon and cecum. This patient had epiploic appendagitis present on the transverse colon near the area that would normally be the splenic flexure (left upper quadrant). This rare location combined with situs ambiguous further complicated the diagnosis.

The treatment of epiploic appendagitis in the nonseptic case is usually conservative. Surgical intervention and antibiotic therapy can be avoided in most uncomplicated cases. Oral anti-inflammatory medications are used to decrease any associated pain. It is usually a benign self-limited diagnosis but there has been one reported death related to epiploic appendagitis (20).

TEACHING POINT

Epiploic appendagitis may have a similar clinical presentation to appendicitis or diverticulitis but can often be distinguished on a CT scan (with IV contrast), US, or MR. Correctly diagnosing epiploic appendagitis utilizing radiological imaging allows conservative treatment with anti-inflammatory medications and avoidance of unnecessary surgical intervention.

REFERENCES

- Sand M, Gelos M, Bechara FG, Sand D, Wiese TH, Steinstresser L, Mann B. Epiploic appendagitis-clinical characteristics of an uncommon surgical diagnosis. *BMC Surgery* 2007;7:11
- Linkenfeld, F. *Deutsche Ztschr f Chir* 1908;92:383.
- Lynn TE, Dockerty MB, Waugh JM. A clinicopathologic study of the epiploic appendages. *Surg Gynecol Obstet* 1956;103:423-33.

- Marinis TP, Cheek JH. Primary inflammation of the appendices epiploicae. *Ann Sur* 1949;129:533-7.
- Ozkurt H, Karatag O, Karaarslan E, Rozanes I, Basak M, Bavbeck C. CT findings in epiploic appendagitis. *Surgery* 2007;141:530-532.
- Sing AK, Gervais DA, Hahn PF, Rhea J, Mueller PR. CT appearance of acute appendagitis. *AJR* 2004;183:1303-1307.
- van Brenda Vriesman AC, Puylaert JB. Epiploic appendagitis and omental infarction: pitfalls and look-a-likes. *Abdom Imag* 2002;27:20-28.
- Sing AK, Gervais DA, Hahn PF, Sagar P, Mueller PR, Noveline RA. Acute epiploic appendagitis and its mimics. *Radiographics* 2005;25:1521-1534.
- Zissin R. CT diagnosis of an acute epiploic appendagitis in a redundant sigmoid colon clinically suspected as acute appendicitis. *The Israel Medical Association Journal* 2003;5:835-836.
- Rao PM, Rhea JT, Novelline RA, et al. Helical CT with only colonic contrast material for diagnosing diverticulitis; prospective evaluation of 150 patients. *AJR* 1998; 170:1445-1450.
- Hanson JM, Kam AW. Paracolic echogenic mass in a man with lower abdominal pain. Is epiploic appendagitis more common than previously thought? *Emerg Med J* 2006;23:e17
- Danse EM, Van Beers BE, Baudrez V, et al. Epiploic appendagitis: color Doppler sonographic findings. *Eur Radiol* 2001;11(2):183-186.
- Sirvanci M, Balci NC, Karaman K, Duran C, Karakas E. Primary epiploic appendagitis: MRI findings. *Magn Reson Imaging* 2002;20(1):137-139.
- Fulcher AS, Turner MA. Abdominal Manifestations of situs anomalies in adults. *Radiographics* 2002; 22(6):1440.
- Rose V, Izukawa T, Moes CAF. Syndromes of asplenia and polysplenia: a review of cardiac and non-cardiac malformations in 60 cases with special reference to diagnosis and prognosis. *Br Heart J* 1975, 37: 840-52.
- Van Praagh R, Weinberg PM, Smith SD, et al. Malpositions of the heart. In: Adams FH, Emmanoulides GC, Riemenschneider TA, eds. *Moss' heart Disease in Infants, Children, and Adolescents*. 4th ed, Baltimore: Williams&Wilkins, 1989, 530-80.
- Strife JL, Bisset GS, Burrows PE. Cardiovascular system. In: Kirks DR, ed. *Practical pediatric imaging: diagnostic radiology of infants and children*. 3rd ed. Philadelphia, Pa: Lippincott-Raven, 1998; 524-527, 588-590.
- Abut E, Arman A, et al. Malposition of internal organs: A case of situs ambiguous anomaly in an adult. *Turk J Gastroenterol*; 2003; 14(2):154.

19. Applegate KE, Goske MJ, Pierce G, Murphy D. Situs revisited: imaging of the heterotaxy syndrome. Radiographics 1999;19:837-852.

20. Murdie W. Intra-abdominal torsion of an appendix epiploicae. Br J Surgery 1953;41:290-5.

FIGURES

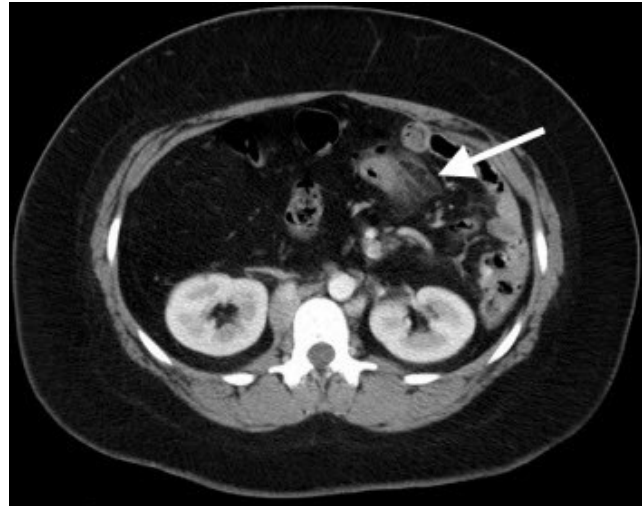


Figure 2: Computed Tomography: A 23 year-old female patient with epiploic appendagitis. The axial CT with IV and rectal contrast shows epiploic appendagitis (arrow) as a pericolic fat attenuated mass with surrounding inflammatory changes. (Radiocontrast 100cc IV dose of Iohexol 350 mg, and gastrografin enema).

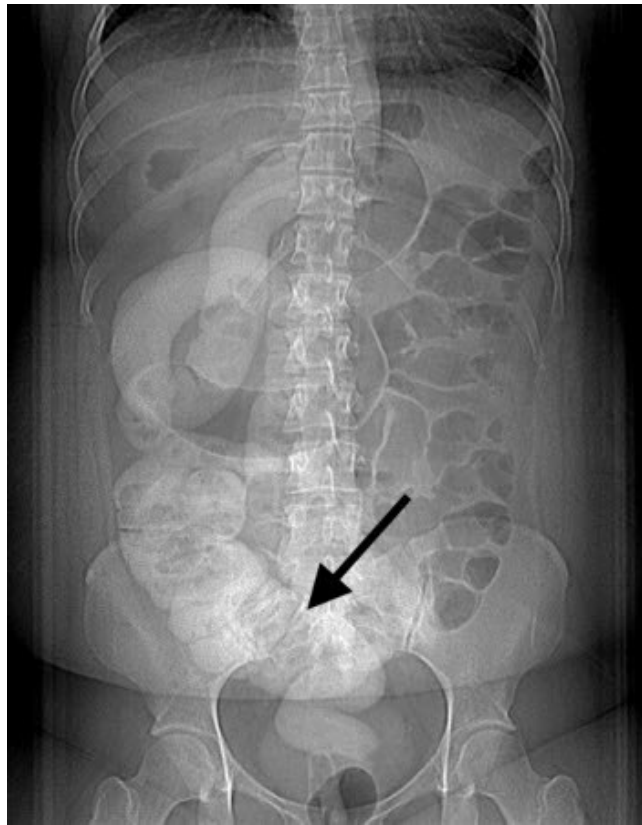


Figure 1: Computed Tomography: A 23 year-old female patient with situs ambiguous abnormality is shown on contrast enhanced CT topogram. The sigmoid colon is distinguished in the right lower quadrant by the arrow. The odd position of the colon is due to situs ambiguous.

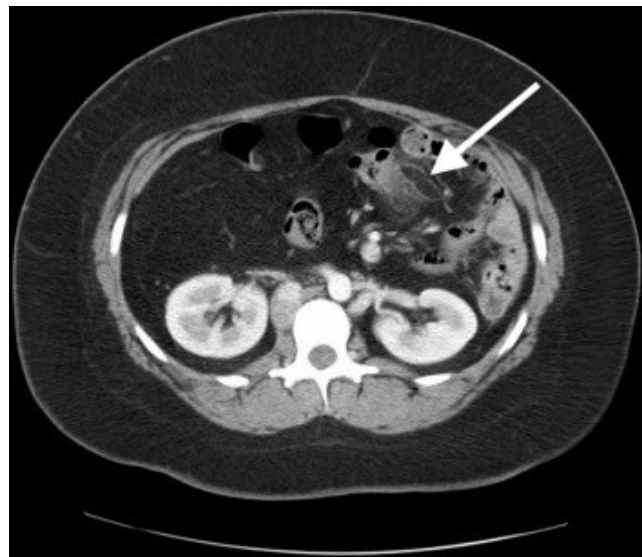


Figure 3: Computed Tomography: A 23 year-old female patient with epiploic appendagitis shown on axial CT with IV and rectal contrast. The epiploic appendagitis is shown as a 2.8 x 0.8 cm fat attenuated mass surrounded by inflammatory changes, which is shown by the arrow. (Radiocontrast 100cc IV dose of Iohexol 350 mg and gastrografin enema).

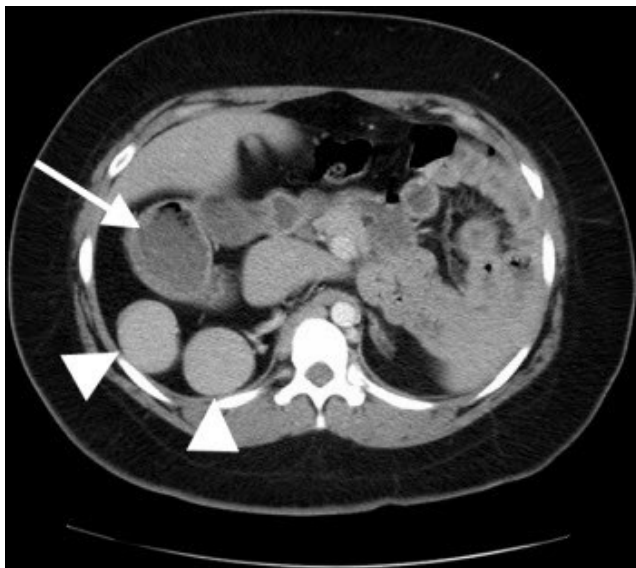

Figure 4: Computed Tomography: A 23 year-old female patient with situs ambiguous with polysplenia. Axial CT with IV contrast shows location of duodenum coming off of the stomach (arrow) located in the right abdomen. Polysplenia is present with splenic tissue (arrowheads) in two distinct locations.

ABBREVIATIONS

CT = Computed Tomography
 US = ultrasonography
 MR = Magnetic Resonance
 WBC = White Blood Cell

KEYWORDS

epiploic appendagitis, epiploic appendage, epiploic appendices, appendix epiploica, appendices epiploicae, situs, situs solitus, situs inversus, situs ambiguous, situs ambiguus, heterotaxy, polysplenia, asplenia: appendicitis

ACKNOWLEDGEMENTS

I would like to thank Dr. D. Kent McNutt for his continued support and KCUMB medical student Jasmine El-Khatib for her past work and inspiration.

Online access

This publication is online available at:
www.radiologycases.com/index.php/radiologycases/article/view/282

Interactivity

This publication is available as an interactive article with scroll, window/level, magnify and more features.
 Available online at www.RadiologyCases.com

Published by EduRad



www.EduRad.org