

# Imaging Features of Renal Hydatid Cyst Presenting with Hydatiduria

Muhammad Umar Amin<sup>1\*</sup>, Khalid Siddique<sup>2</sup>, Pervaiz Ahmad Aftab<sup>3</sup>

1. Radiology and Imaging Department, Combined Military Hospital, Attock, Pakistan

2 Department of Surgery. Combined Military Hospital, Bahawalpur, Pakistan

3 Department of Surgery. Combined Military Hospital, Bahawalpur, Pakistan

\* **Correspondence:** Dr. Muhammad Umar Amin, MBBS, FCPS, Radiology and Imaging Department, Combined Military Hospital, 43600 Bahawalpur, Pakistan (✉ [umar1971@hotmail.com](mailto:umar1971@hotmail.com))

Radiology Case. 2009 Mar; 3(3):6-11 :: DOI: 10.3941/jrcr.v3i3.128

## ABSTRACT

We report a case of renal hydatid cyst in a 25-year-old male who presented with hydatiduria. Intravenous pyelography revealed presence of a space-occupying lesion in the lower pole of right kidney with curvilinear calcifications. Ultrasound, computed tomography and MRI were suggestive of hydatid cyst in the right kidney. Patient underwent right-sided nephrectomy. Passage of hydatid cysts in urine is an exceedingly rare occurrence. Urinary tract involvement develops in 2-4% of all cases of hydatid cyst. Hydatiduria is an extremely rare manifestation of renal hydatid cyst. We report such a case with emphasis on IVU, sonographic, CT and MRI findings.

## CASE REPORT

### CASE REPORT

A 25 years old male presented with complaints of pain in the right renal area and passage of grape like structures in the urine for past one year. Investigations performed included urine analysis, serological tests, eosinophil count and relevant radiological studies. Macroscopic examination of urine revealed grape like whitish structures which after some time lost there rounded shape in urine and collapsed (Fig.1). Ultrasound of the abdomen was performed with a 3.5 MHz probe which showed a large multicystic structure replacing lower two thirds of the right kidney (Fig. 2). It measured 8.3 x 5 x 8 cm approximately. Solid avascular component was also seen within the lesion. Upper pole of right kidney was hydronephrotic with renal parenchymal loss. The cyst was avascular on Color Doppler study (Fig. 2). Left kidney, liver, spleen and rest of the abdomen were normal sonographically. Intravenous pyelography was performed which revealed slightly delayed excretion of contrast from the right kidney

with presence of a space occupying lesion in the lower pole. Two curvilinear calcified walls were seen in the inferior portion of this lesion (Fig. 3). The Proximal right ureter was narrowed with resultant hydronephrosis involving the upper pole. The left kidney had a normal function.

CT scan of the abdomen was performed which revealed moderately hydronephrotic upper pole of the right kidney and a large multiloculated cystic lesion with a small portion extending into the anterior pararenal space (Fig. 4). Magnetic resonance (MR) imaging was performed to reveal exact extent of the cystic structure and to visualize the lesion in different planes. T1- weighted sequence revealed a hypointense multicystic lesion (Fig. 5). T2-weighted sequence revealed a hyperintense signal intensity multicystic structure (Fig. 6-8). The small peripheral cysts were hyperintense on T2-weighted sequences. No gadolinium-based contrast material was administered. Indirect haemagglutination test (IHA) was negative and there was no eosinophilia. Based on these findings, a diagnosis of hydatid cyst was made.

Albendazole, 10 mg/kg per day, was given for 4 weeks (2 weeks preoperatively and 2 weeks postoperatively). Right sided nephrectomy was performed without cyst perforation or any spilling of cyst content. The specimen was removed en bloc. (Fig.9-A). During surgery, the liver was normal in appearance, and no other hydatid cysts were seen in the abdomen. Gross pathologic examination showed a large white cyst containing clear fluid and daughter cysts of varying size (Fig. 9-B, 10). These findings confirmed the diagnosis of primary hydatid cyst of the left kidney. Histopathology also confirmed the typical features of hydatid cyst.

### DISCUSSION

Echinococcosis is a worldwide zoonosis produced by the larval stage of the *Echinococcus* tapeworm. The adult worm lives in the proximal small bowel of the definitive host, attached by hooklets to the mucosa. Eggs are released into the host's intestine and excreted in the feces. Humans may become intermediate hosts through contact with a definitive host (usually a domesticated dog) or ingestion of contaminated water or vegetables. In humans, hydatid disease involves the liver in approximately 75% of cases and the lung in 15%. Secondary involvement due to hematogenous dissemination may be seen in almost any anatomic location. Kidney involvement in echinococcosis is extremely rare (2%–3% of cases), even in areas where hydatid disease is endemic. Renal hydatid cysts usually remain asymptomatic for many years. There are no pathognomonic clinical signs except cystic rupture into the collecting system, which leads to acute renal colic and hydatiduria (1).

Radiological studies have an important place in the preoperative diagnosis of renal hydatid disease. However, there is no specific sign on plain radiography or intravenous urography, and ultrasound or computed tomography cannot always show hydatidosis as a specific lesion. Therefore, it is sometimes difficult to differentiate between a unilocular hydatid cyst without mural calcification and a simple renal cyst (2). Calcification of the cyst is not restricted to the inactive cyst types, but occurs in all stages and in up to 50% of cysts (3). Intravenous urography may reveal caliceal distortion, caliectasis or nonfunctioning kidney in renal hydatid disease. Ultrasonography shows a complex cyst in all of the patients.

Advanced radiologic techniques such as CT and MR imaging remain the mainstays of diagnosis (8,9). Computed tomography may demonstrate multivesicular cystic structure, complex cyst or simple cyst (4). Lesions with a solid appearance may be encountered. Lack of internal contrast enhancement allows one to classify them as hyperattenuating or hyperintense cystic lesions and to avoid misinterpreting them as tumors.

In general, surgery is the treatment of choice in renal hydatid cyst. Kidney-sparing surgery (cystectomy with pericystectomy) is possible in most cases (75%). Nephrectomy (25% of cases) must be reserved for destroyed kidneys (5). A major concern during surgery for cyst removal is that, if a cyst ruptures, the brood capsules can spread throughout the body, and secondary cysts can grow wherever their contents come to rest. Although puncture of hydatid cyst has been considered as a possible source of anaphylactic reactions and spread of the

parasite, studies have shown good long-term results with percutaneous hydatid cyst treatment under US guidance (6,7).

If a hydatid cyst ruptures into the collecting system, the disease can spread to the ureters or bladder (10).

This disease process presents both diagnostic and treatment difficulties that can be overcome with greater awareness. So, despite its rarity, hydatid disease should be included in the differential diagnosis of cystic lesions in solid organs or other anatomic sites, especially in endemic countries.

### TEACHING POINT

Macroscopic hydatiduria is an unusual complication of renal hydatid disease and imaging techniques can easily reveal extent of the renal involvement by hydatid cysts.


### ABBREVIATIONS

MRI= Magnetic Resonance Imaging  
 IVU = Intravenous urography  
 CT =Computed tomography  
 KUB=Kidneys urinary bladder  
 US = Ultrasound

### REFERENCES

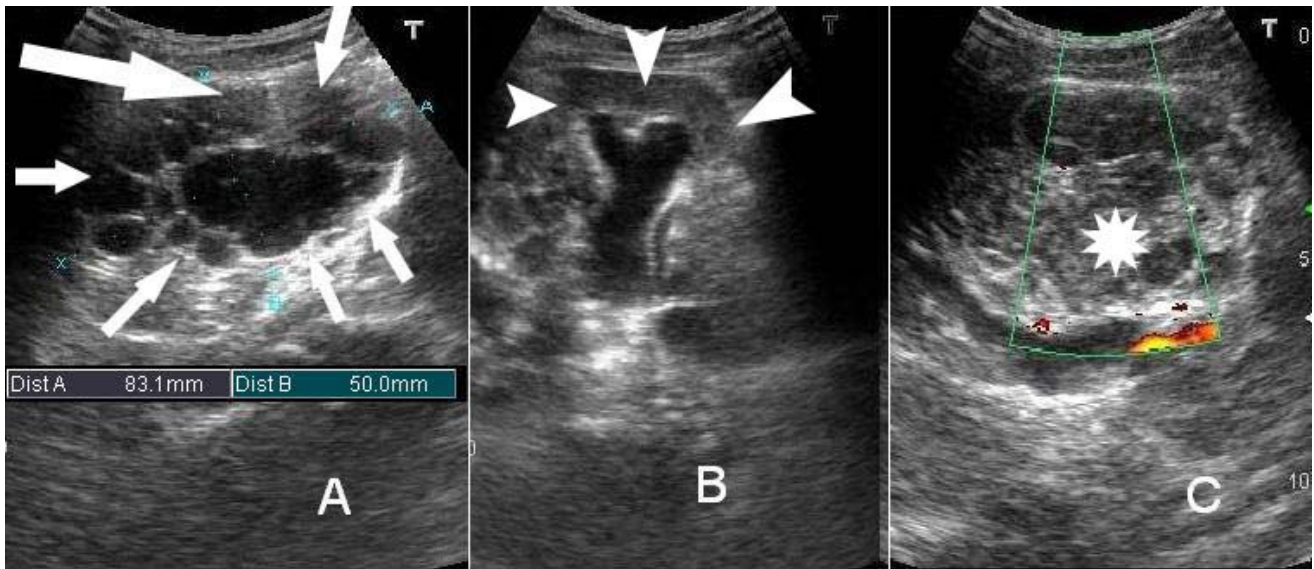
1. Wim K. Volders, Geert Gelin, Relinde C. Stessens. Best Cases from the AFIP Hydatid Cyst of the Kidney: Radiologic-Pathologic Correlation. *Radiographics*. 2001; 21:255-60.
2. Mete Kilciler, Selahattin Bedir, Fikret Erdemir, Hidayet Coban, Burak Sahan, Yasar Ozgok. Isolated Unilocular Renal Hydatid Cyst: A Rare Diagnostic Difficulty with simple Cyst Urologia Internationalis 2006; 77:371-74.
3. Hosch W, Stojkovic M, Janisch T, Kauffmann GW, Junghans T. The role of calcification for staging cystic echinococcosis (CE). *Eur Radiol* 2007; 17(10): 2538-45.
4. Zargar-Shoshtari M, Shadpour P, Robat -Moradi N, Moslemi M. Hydatid cyst of urinary tract: 11 cases at a single center. *Urol J*. 2007; 4(1): 41-5.
5. Zmerli S, Ayed M, Horchani A, Chami I, El Ouakdi M, Ben Slama MR. Hydatid cyst of the kidney: diagnosis and treatment. *World J Surg* 2001; 25:68-74.
6. Akhan O, Ustunsoz B, Somuncu I, et al. Percutaneous renal hydatid cyst treatment: long-term results. *Abdom Imaging* 1998; 23:209-213.
7. Ustunsoz B, Akhan O, Kamiloglu MA. Percutaneous treatment of hydatid cysts of the liver: long-term results. *AJR Am J Roentgenol* 1999; 172:91-96.
8. Von Sinner WN, Hellstrom M, Kagevi I, Norlen BJ. Hydatid disease of the urinary tract. *J Urol* 1993; 149:577-580.
9. Odev K, Kilinc M, Arslan A, et al. Renal hydatid cysts and the evaluation of their radiologic images. *Eur Radiol* 1996; 30:40-49.
10. Pinar Polat, Mecit Kantarci, Fatih Alper, Selami Suma, Melike Bedel Koruyucu, Adnan Okur, Hydatid Disease from Head to Toe. *Radiographics*. 2003; 23:475-494.

FIGURES



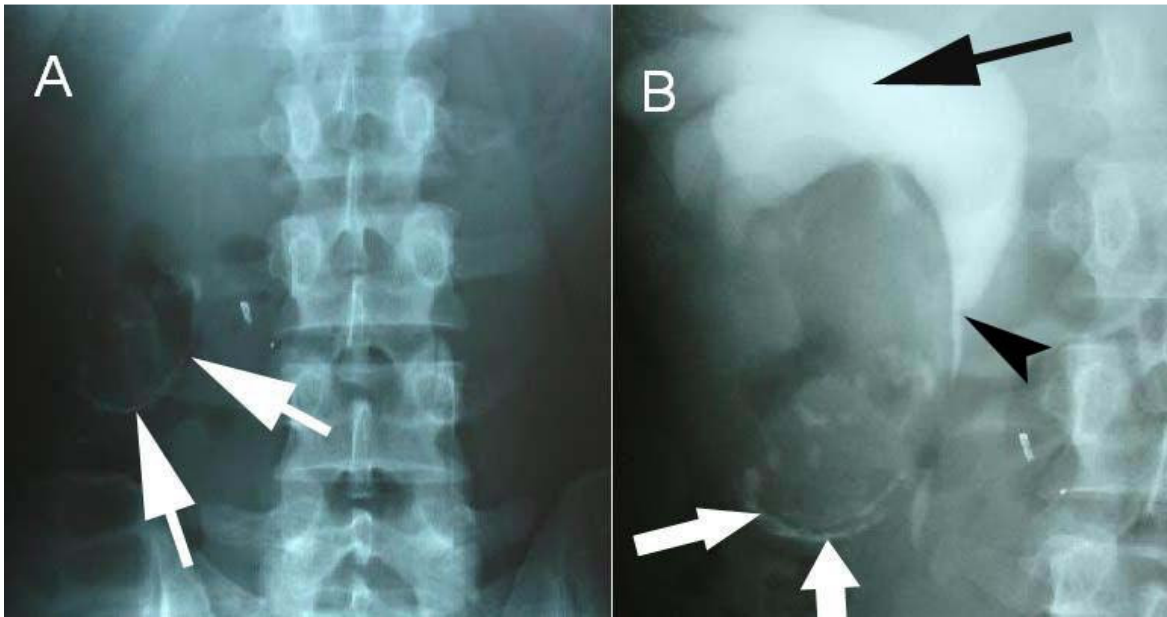
**Figure 1 (left):** 25 year old male with renal hydatid cyst. Patient's urine sample revealed hydatiduria seen as whitish material partially dissolved in the urine. (Black arrow).

**Figure 2 (bottom):** 25 year old male with renal hydatid cyst. US of the right kidney. Grayscale scan (A). Kidney is replaced by a multiseptated cystic structure (arrows). (B) Upper pole of the kidney revealed hydronephrosis (arrowheads). Color Doppler scan (C) No flow was seen in the lesion on Color Doppler study. Observe the solid component within the lesion (asterisk)

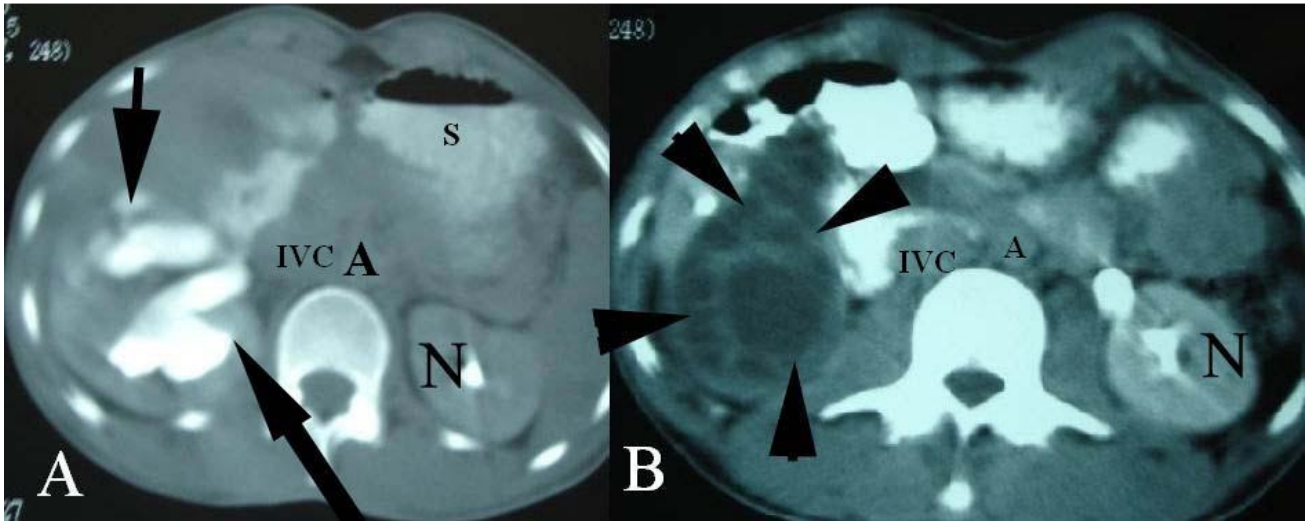


Journal of Radiology Case Reports

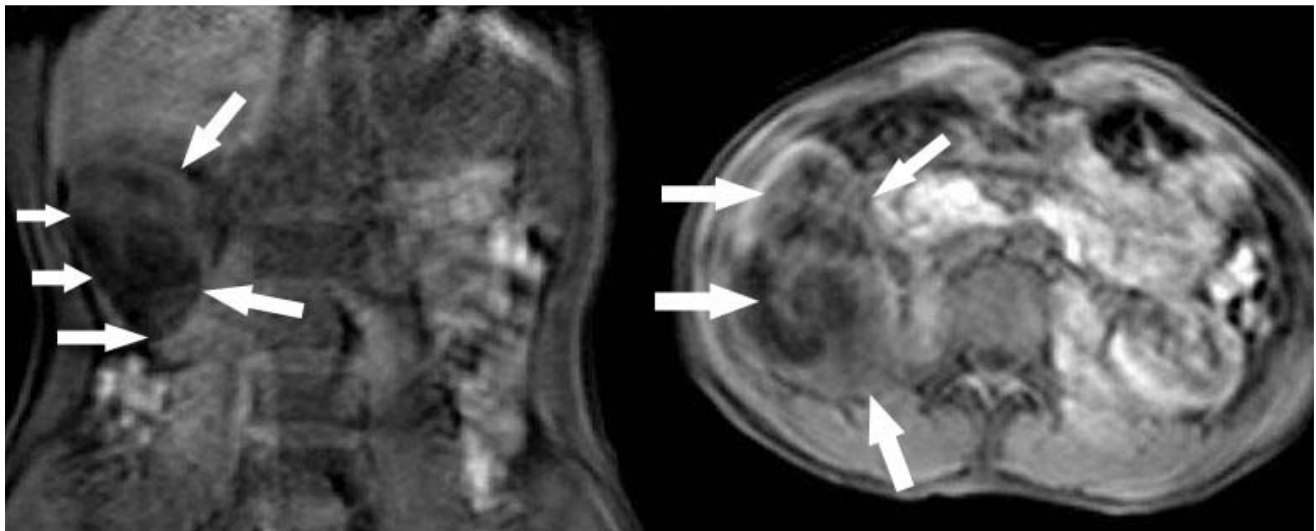
www.RadiologyCases.com



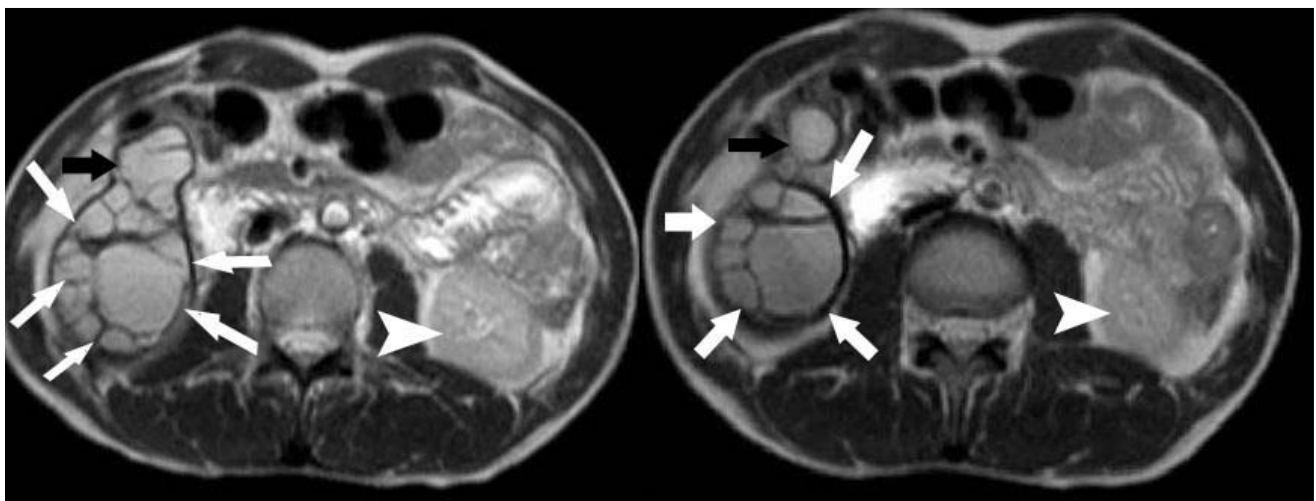
**Figure 3:** 25 year old male with renal hydatid cyst. (A) KUB film showing curvilinear calcification in the renal area (white arrow). (B) IVU demonstrating the hydronephrotic upper pole (Black arrow). Curvilinear calcification seen in the lower pole of the right kidney (white arrows). Observe abrupt narrowing at the ureterovesical junction (Black arrowhead).



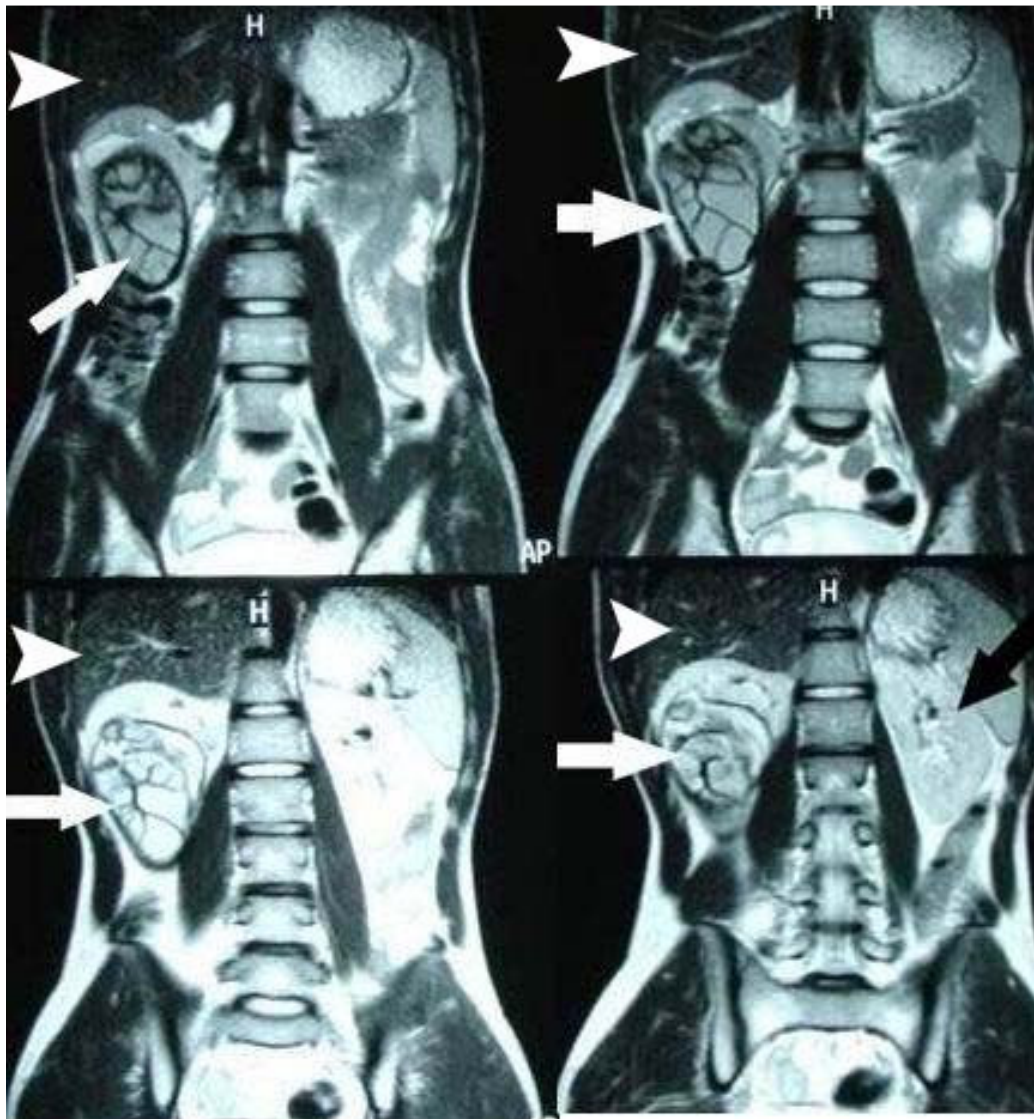
**Figure 4:** 25 year old male with renal hydatid cyst. (A)CT scan of the abdomen showing hydronephrotic upper pole (black arrows). (B)Multiloculated hypoattenuating thin-walled cystic lesion (arrowheads). N=Normal Left Kidney.A=Aorta, IVC=Inferior Vena, Cava S=Stomach



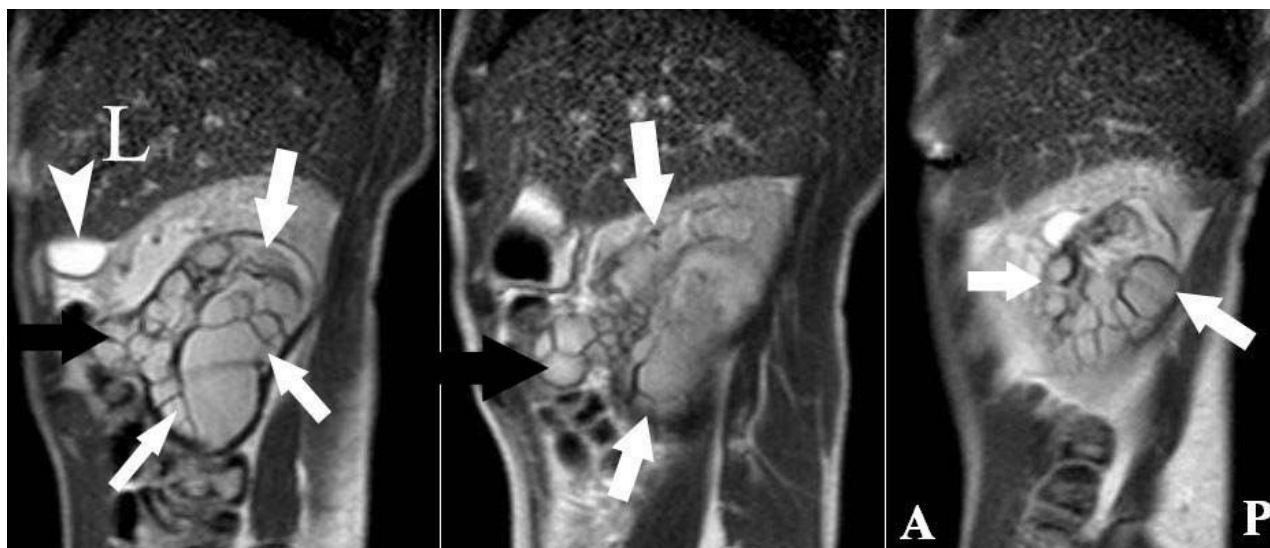**Figure 5:** 25 year old male with renal hydatid cyst. (A).Coronal (B) Axial T1W weighted image obtained on a 1.5 T MRI scanner. MRI showing hypointense lesion in the right kidney (arrows).



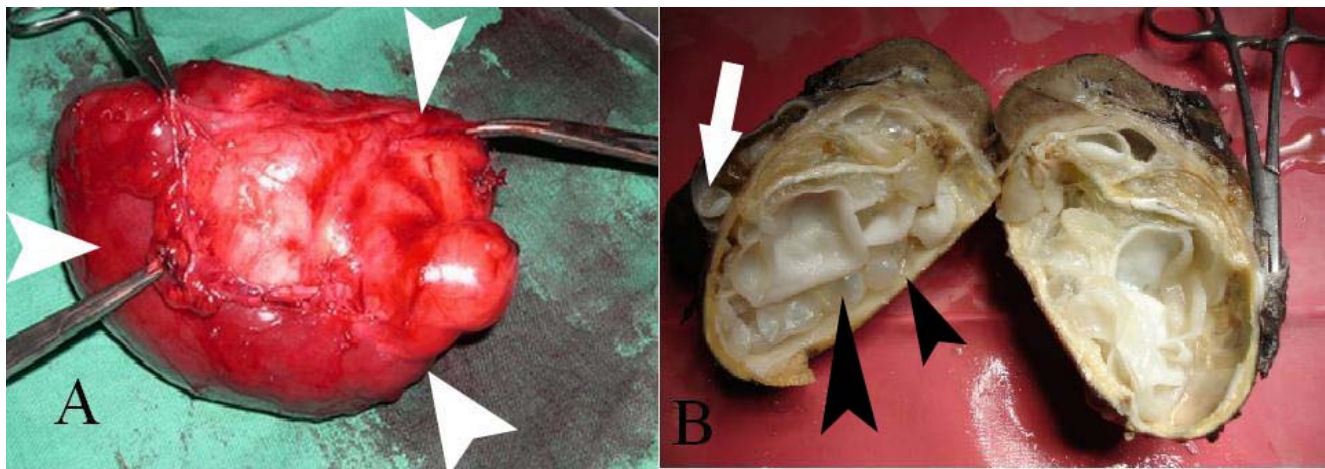
**Figure 6:** 25 year old male with renal hydatid cyst. Axial T2-weighted image obtained on a 1.5 T MRI scanner. Note hyperintense signal from cystic contents as well as hypointense septae. Arrowhead = Normal left kidney. Observe anterior bulge from the main cyst (black arrow).



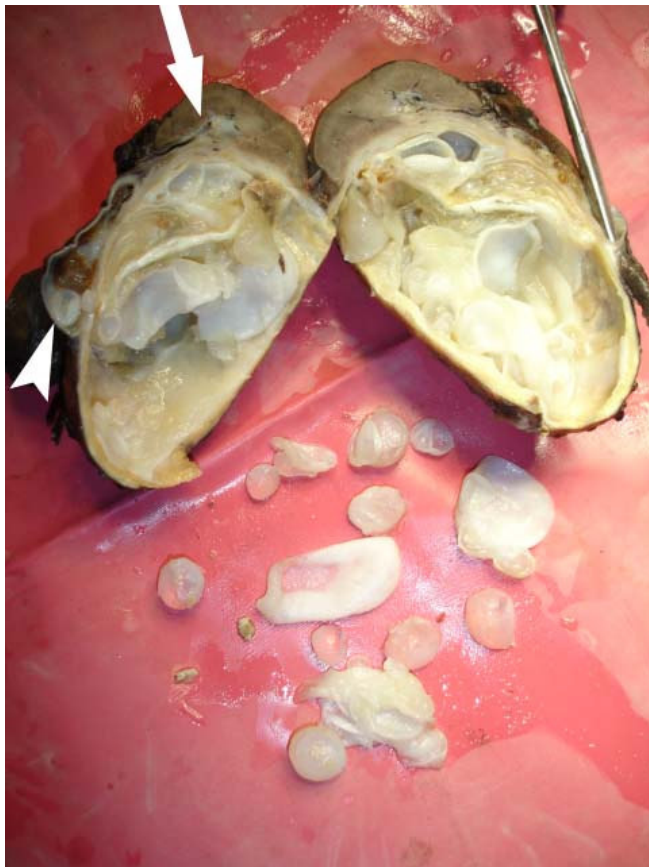
**Figure 7:** 25 year old male with renal hydatid cyst. Coronal T2-weighted image obtained on a 1.5T MRI machine. White arrow = Hydatid cyst of right kidney. Observe hypointense septae due to formation of daughter cysts. Black arrow = Normal left kidney. Arrowhead= Normal looking liver.



**Figure 8:** 25 year old male with renal hydatid cyst. Sagittal T2-weighted image obtained on a 1.5T MRI scanner. Hydatid cyst of right kidney (arrows). Observe anterior bulge from the main cyst containing small daughter cysts (black arrow). L=Liver, A=Anterior P=Posterior. Arrowhead =Gall bladder



**Figure 9:** 25 year old male with renal hydatid cyst. (A) Post-operative Nephrectomy specimen. (B) Cut section of the kidney. Hydatid cyst can be seen in the dilated renal pelvis (arrow). Note the grape like cystic lesions (black arrowheads).



**Figure 10:** 25 year old male with renal hydatid cyst. Hydatid cyst along with daughter cysts. Arrowhead = Dilated renal pelvis containing small daughter cysts. Only upper pole of the kidney is spared (arrow)

KEYWORDS

Hydatid cyst, hydatiduria ,hydronephrosis, multiloculated

Online access

This publication is online available at:  
[www.radiologycases.com/index.php/radiologycases/article/view/128](http://www.radiologycases.com/index.php/radiologycases/article/view/128)

Interactivity

This publication is available as an interactive article with scroll, window/level, magnify and more features.  
 Available online at [www.RadiologyCases.com](http://www.RadiologyCases.com)

Published by EduRad



[www.EduRad.org](http://www.EduRad.org)