

Dracunculiasis of the Breast: Radiological Manifestations of a Rare Disease

Shannon K. Barry^{1*}, William Gregory Schucany¹

1. Department of Radiology, Baylor University Medical Center at Dallas, Dallas, TX, USA

* **Correspondence:** Shannon K. Barry, Baylor University Medical Center at Dallas, Department of Radiology, 3500 Gaston Avenue, Dallas, TX, 75204, USA

(✉ shannon.barry4@gmail.com)

Radiology Case. 2012 Nov; 6(11):29-33 :: DOI: 10.3941/jrcr.v6i11.1137

ABSTRACT

Dracunculiasis of the breast is a rare manifestation of prior infection with the parasite *dracunculus medinensis* (guinea worm). We describe a case of a 60-year-old woman, who had recently emigrated from Cameroon. She presented for an annual screening mammogram and was found to have coarse linear or coiled serpiginous calcifications. These findings were recognized as calcified guinea worms within the breast tissue. This case report aims to highlight the mammographic findings of this rare infectious disease.

CASE REPORT

CASE REPORT

A 60-year-old woman who had moved to the United States from Cameroon presented for an annual screening mammogram. The patient had no signs or symptoms of breast disease. Her past medical history was positive for remote *dracunculus medinensis* infection.

Bilateral screening mammogram was performed with craniocaudal and mediolateral oblique views of both breasts. Both breasts demonstrated calcifications. The left breast demonstrated two linear serpiginous focal calcifications. The right breast demonstrated calcifications along the 10 o'clock axis, 7-8 cm from the nipple. Although benign calcifications were suspected, further evaluation with magnification views was recommended.

A diagnostic mammogram of both breasts was performed. Focal spot magnification views demonstrated calcifications in the upper outer quadrant of the right breast, consistent with dermal calcifications. In addition, coarse linear calcifications of both breasts were also demonstrated which had a coiled or serpiginous linear appearance. Given the patient's past medical history of prior infection with *dracunculus medinensis*, these findings were recognized as being characteristic for dracunculiasis of the breast. Routine annual mammogram was

recommended, as the findings are a sequela of prior infection, and do not indicate active infection.

DISCUSSION

Dracunculiasis is a parasitic infection caused by *dracunculus medinensis*, also known as the guinea worm [1]. The infection is contracted by drinking water from ponds contaminated by copepods (water fleas) that contain immature forms of the parasite. After ingestion, the larvae penetrate the intestinal mucosa and migrate into the subcutaneous tissues. Female worms emerge through skin lesions, usually on the lower limbs [2]. Larvae are released into the water by the emerging worm to continue the life cycle. There is no known treatment for dracunculiasis and preventive measures have been applied in attempts for eradication.

There are several historical references to this infection including the Old Testament of the Bible, and ancient Greek texts. Historically, once the worm emerged from the wound, it would be pulled out a few centimeters each day with gentle pressure, while wrapping the worm around a stick. One of the symbols of modern medicine depicts this form of treatment, known as the Rod of Asclepius. If the infection is identified before an ulcer forms, the worm can be surgically removed [3].

Immature female worms can die in transit and calcify. The migration of the worm to the breast tissue remains very rare [2].

Once prevalent in 20 nations in Asia and Africa, the disease, according to a recent article in the Journal of the American Medical Association, remains endemic only in 3 countries: Sudan, Mali, and Ethiopia, which have limited or no access to clean water [4]. Distribution of the disease remains isolated to sub-Saharan Africa. Eradication measures recommended by World Health Organization include mapping of all endemic villages and establishing community-based surveillance systems in every known endemic village, implementing effective case containment measures in all endemic villages, implementing specific interventions such as ensuring access to safe water, health education, community mobilization, filters and providing vector control of potential unsafe water sources with temephos insecticide (Abate®). To measure the effectiveness of the eradication measures the World Health Organization also recommends reporting on a regular basis, even if zero cases, maintaining global and national dracunculiasis databases to monitor the epidemiological situation, and managing the certification process for global eradication country by country. In 1989, Cameroon began hosting events, today known as National Guinea Worm Days, promoting interventions consisting of active surveillance, social mobilization, health education, distribution of filters, construction of new water sources, chemical treatment of unsafe water sources, and case containment [5]. In 2007, the World Health Organization certified Cameroon as free of Guinea worm disease.

There are no cases of dracunculiasis of the breast diagnosed in the United States described in the literature. There are two cases described in the United Kingdom. Hamilton and Evans describe a patient with breast calcifications detected on screening mammogram in a Nigerian woman who moved to the UK. The patient had calcified worms within both breasts and no symptoms attributable to these calcifications; however, the patient did have a history of prior dracunculiasis infection and removal 10 years previously in Nigeria [6]. Bin Saleem and Ahmed describe a case of dracunculiasis of the breast in a Kenyan woman who presented to a surgical outpatient clinic with a painless lump in the right breast. On clinical examination she was found to have an irregular lump under her right nipple. Mammogram showed a calcified Guinea worm under the right nipple without any suspicion of malignancy [2]. The condition requires no treatment, as the calcified worms are no longer viable and do not indicate active disease. However, they may be mistaken for another etiology, which would lead to unnecessary intervention, such as biopsy.

Our case of dracunculiasis of the breast is the first case described in the United States. A pertinent clinical history of emigration from Cameroon, a country where dracunculiasis was once endemic, proved to be of great value in the correct diagnosis in this case. Dracunculiasis is a rare disease that has specific radiological manifestations and should be a consideration in patients who have recently emigrated from countries where dracunculiasis infection is endemic, or from

countries where eradication occurred after the patient immigrated to the United States. The radiological significance of this condition is in recognizing that is a sequela of a prior infection and does not represent an entity that would require further evaluation, which may lead to an unnecessary invasive procedure, such as biopsy. The differential diagnosis includes other entities that cause calcifications of the breast, such as arterial or vascular calcifications, intraductal calcifications, prior mastitis, remote trauma, fibroadenoma, and calcified sutures. These various diagnoses have specific imaging characteristics that allow them to be differentiated from one another. In this patient, the most pertinent finding was the patient's positive history of prior dracunculiasis infection and negative history of any prior surgical intervention.

TEACHING POINT

Dracunculiasis of the breast is a rare disease that manifests as coarse linear calcifications that have a coiled or serpiginous linear appearance on mammogram. This diagnosis should be a consideration in patients who have recently emigrated from countries where dracunculus medinensis infection is endemic, or from countries where eradication occurred after the patient immigrated to a non-endemic country.

REFERENCES

1. James, WD, Berger TG. Andrews' Disease of the Skin: Clinical Dermatology. Saunders Elsevier. 2006; 437.
2. Bin Saleem, T. & Ahmed, I. J Ayub Med Coll Abbottabad. 2006; 18(4). PMID: 17591014.
3. Stelling C. Dracunculiasis Presenting as Sterile Abscess. AJR. 1982; 138:1159-1161. PMID: 6211068
4. Voelker R. Global Partners Take Two Steps Closer to Eradication of Guinea Worm Disease. JAMA. 2011; 305(16): 1642. PMID: 21521840
5. Sam-Abbenyi A, Dama M, Graham S, and Obate Z. International Journal of Epidemiology. 1999;28:163-168. PMID: 10195683
6. Hamilton L.J. & Evans A.J. Dracunculiasis: a rare cause of breast calcification detected on screening mammography. Clinical Radiology. 2004; 59(2): 205-206. PMID: 14746793

FIGURES

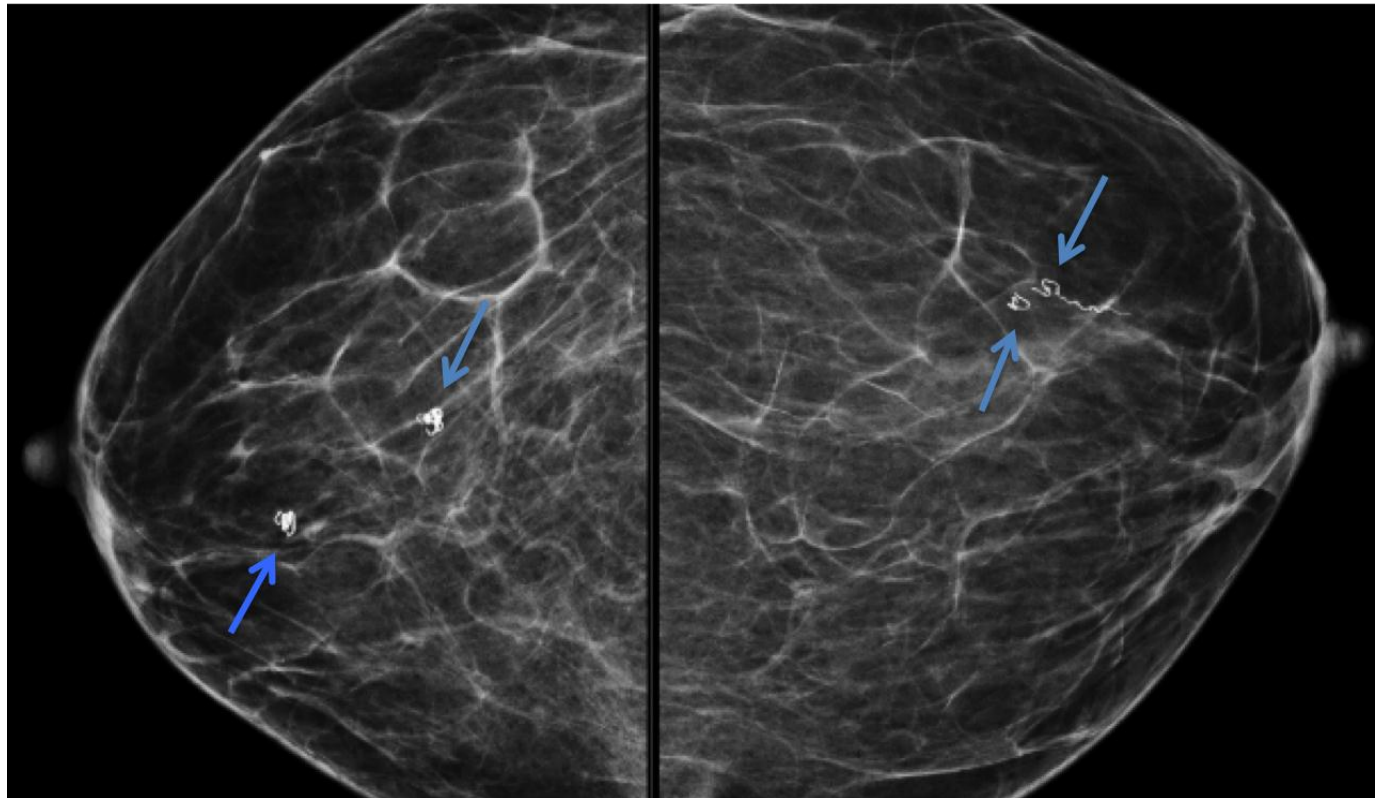


Figure 1: 60-year-old female with dracunculiasis of the breast. Craniocaudal mammogram demonstrates bilateral linear serpiginous focal calcifications.

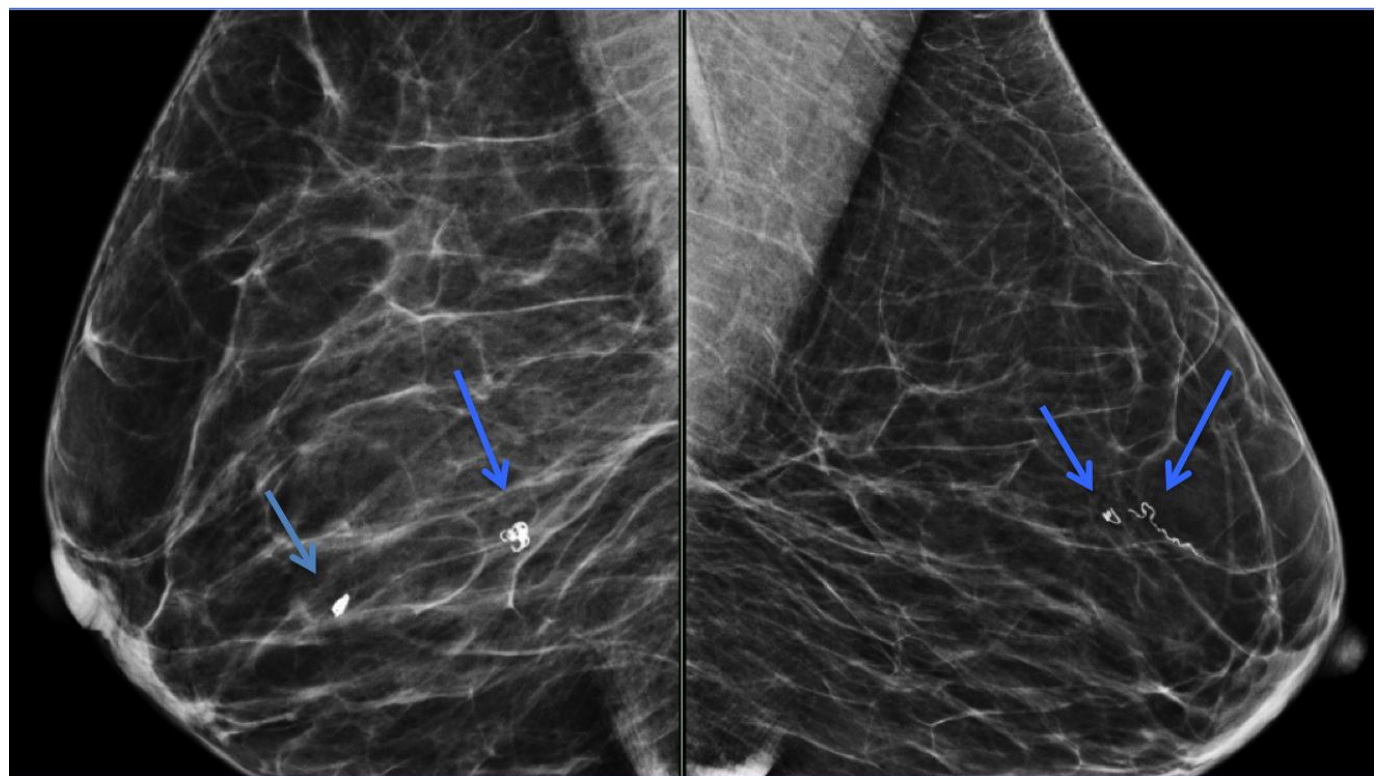


Figure 2: 60-year-old female with dracunculiasis of the breast. Mediolateral oblique mammogram demonstrates bilateral linear serpiginous focal calcifications.

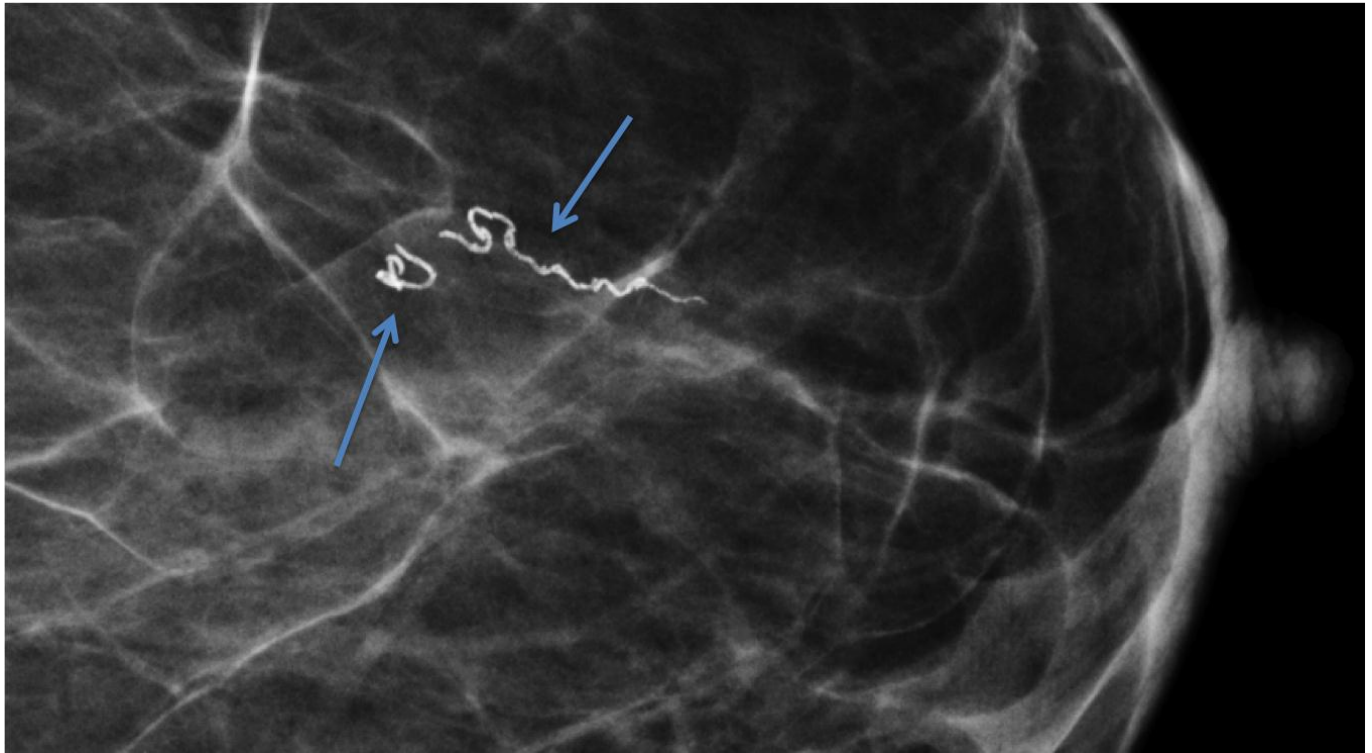


Figure 3: 60-year-old female with dracunculiasis of the breast. Craniocaudal magnification view of the left breast demonstrates two linear serpiginous focal calcifications.

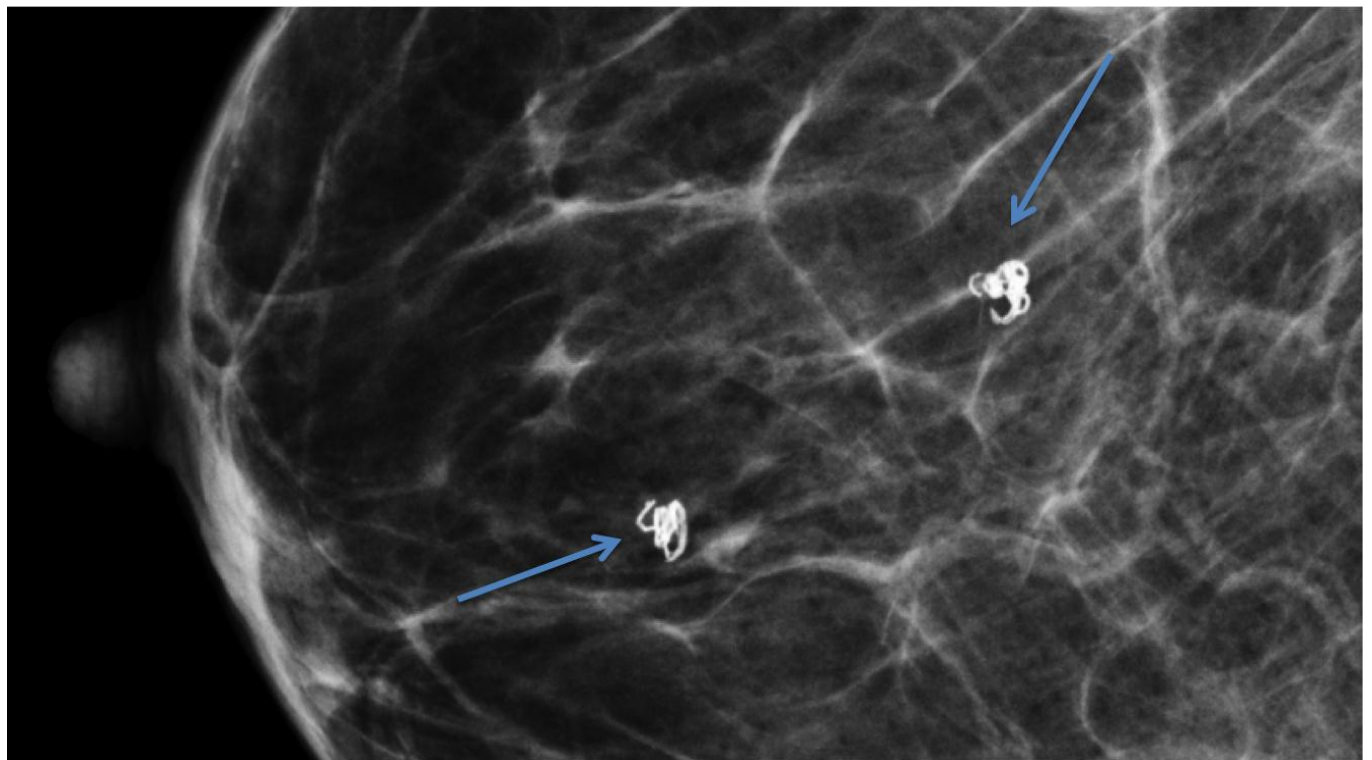


Figure 4: 60-year-old female with dracunculiasis of the breast. Magnification view of the right breast demonstrates two linear serpiginous focal calcifications.

Etiology	Nodular dermatosis produced by the development of Dracunculus parasite in the subcutaneous tissues of mammals
Incidence	1060 in 2011
Gender ratio	No predilection
Age predilection	No predilection
Risk factors	Drinking water contaminated by water fleas (copepods) that host Dracunculus larvae
Treatment	No vaccine or medicine to treat or prevent Guinea worm disease.
Prognosis	Guinea worm disease is usually not fatal, however, the wound where the worm emerges could develop a secondary bacterial infection.
Findings on Imaging	Calcified guinea worms within the soft tissues

Table 1: Summary Table of Dracunculiasis of the Breast

Differential Diagnosis	X-Ray/Mammographic Findings
Arterial/Vascular Calcifications	Thin linear calcifications involving the entire circumference of arteries in breast. “Tram track” appearance.
Intraductal calcifications	Linear calcifications; often branching with malignancy
Prior mastitis/secretory disease	Intra and peri-ductal linear calcifications; bilateral
Oil cyst	Curvilinear egg shell calcification with a clear center
Fibroadenoma	“Popcorn” calcification with dense center
Calcified sutures	Calcifications of differing morphology, may be serpiginous, note: important to elicit history of prior surgery involving the breast

Table 2: Differential Table for Dracunculiasis of the Breast

ABBREVIATIONS

None

KEYWORDS

Dracunculiasis; breast; mammography

Online access

This publication is online available at:
www.radiologycases.com/index.php/radiologycases/article/view/1137

Peer discussion

Discuss this manuscript in our protected discussion forum at:
www.radiolopolis.com/forums/JRCR

Interactivity

This publication is available as an interactive article with scroll, window/level, magnify and more features.
 Available online at www.RadiologyCases.com

Published by EduRad



www.EduRad.org